

## GASTRIC METASTASES OF A MALIGNANT MELANOMA

Talis Shindy Masuda<sup>1</sup>, Victor Antônio Kuiava<sup>1</sup>,  
Paulo Henrique Marques dos Santos<sup>1</sup>, Nilton Maiolini Bonadeo<sup>2</sup>

### ABSTRACT

Malignant melanoma accounts for around 5% of all malignant skin tumors. It is considered one of the most aggressive neoplasms due to its high metastasizing capacity. The most common sites of metastasis are peri-tumor lymph nodes, lung, brain and liver. The digestive tract is not a common site of metastasis. When involved, the small intestine is the organ most commonly affected. The stomach is a rare site of metastasis, found in only 7% percent of the cases. We report a case of a 72-year-old patient with a history of malignant melanoma who presented with acute epigastric pain. Enterotomography, upper endoscopy and additional biopsies confirmed the diagnosis of gastric metastases.

**Keywords:** *Melanocytic cell tumor; malignant melanoma; gastric metastases; digestive tract*

*Clin Biomed Res.* 2019;39(2):179-180

<sup>1</sup> Faculdade de Medicina, Universidade de Passo Fundo (UPF). Passo Fundo, RS, Brasil.

<sup>2</sup> Departamento de Endoscopia, Hospital São Vicente de Paulo (HSVP). Passo Fundo, RS, Brasil.

#### Corresponding author:

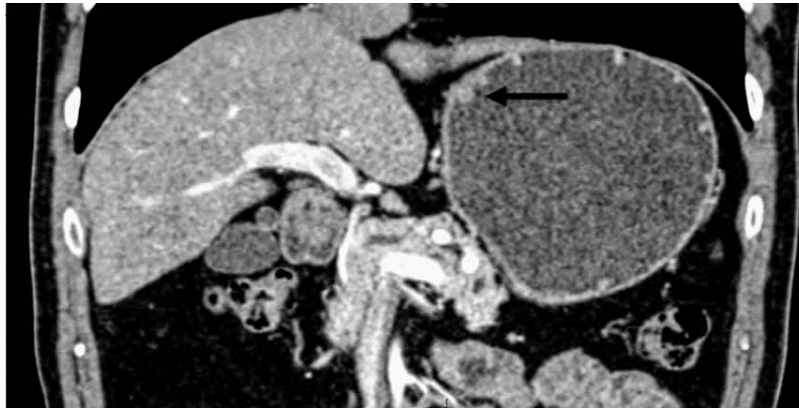Talis Shindy Masuda  
tsmmst@gmail.com  
Rua Teixeira Soares, 817.  
99010-080, Passo Fundo, RS, Brasil.

A 72-year-old patient reported to our department complaining of acute epigastric pain. He had a medical history of cutaneous melanoma on the neck, which had been surgically removed 18 months earlier. The patient was submitted to enterotomography, revealing polypoid lesions in the small and great gastric curvatures, with the largest lesion measuring 10 mm (Figure 1). He was then submitted to upper endoscopy, which indicated the presence of ulcerated lesions on the gastric mucosa (Figure 2). These were confirmed as metastatic disease at histological analysis (Figure 3). The patient is currently undergoing palliative chemotherapy for symptom control.

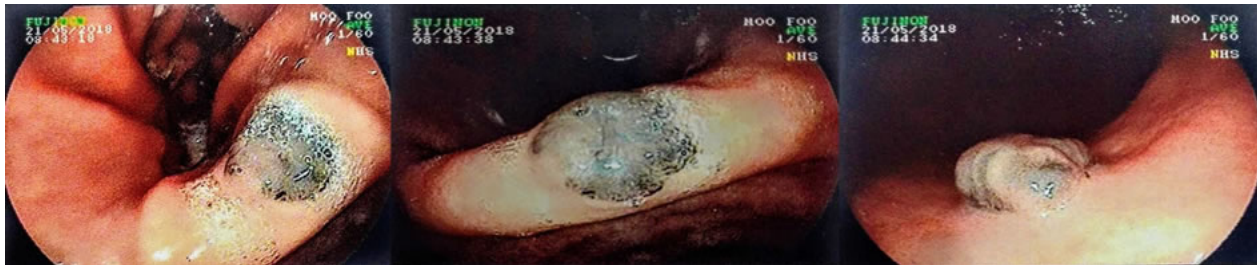
Malignant melanoma is a malignant melanocytic cell tumor of the skin, responsible for about 5% of all malignancies in this organ<sup>1,2</sup>. The incidence increases proportionally with age, presenting a higher prevalence between the fifth and seventh decade of life, affecting men and women indiscriminately. Risk factors include family history, white race, actinic keratoses, and prolonged and excessive exposure to the sun. The most frequent metastatic sites are lymph nodes (73%), lungs (71%), liver (58%), brain (54%), bones (48%) and adrenal glands (46%)<sup>1,3</sup>.

The digestive tract is not a common site of metastasis, but, if diagnosed, the small intestine is most frequently involved. Gastric metastases are found in only 7% of such cases<sup>4,5</sup>. However, among metastases in the gastrointestinal tract, melanoma is the most common tumor, reported in 23% of necropsies. Metastases in the gastrointestinal tract are usually difficult to diagnose, probably due to poor or nonspecific symptoms<sup>1</sup>.

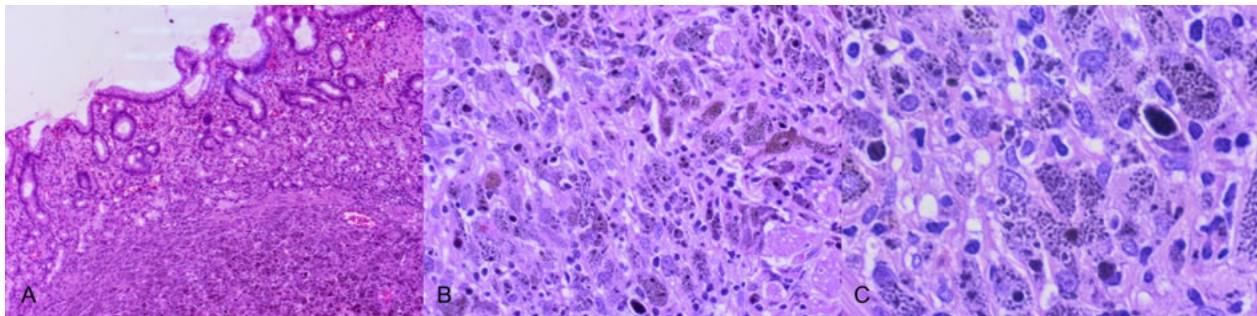
Clinically, patients may present with hemorrhage, perforation or even occlusion. Symptoms include weight loss, dysphagia, hematemesis and melena<sup>5</sup>. Upper endoscopy is characterized by one or more polypoid lesions, generally ulcerated, pigmented or not. Involvement of the small gastric curvature is rare<sup>5</sup>. The prognosis is reserved in patients with metastatic melanoma, with an average survival of 6-8 months.



**Figure 1:** Contrast enterotography demonstrating a polypoid lesion in the small curvature of the stomach (indicated by the arrow).



**Figure 2:** Upper digestive endoscopy identifying pseudopolypoid lesions with blackened surface in the gastric mucosa.



**Figure 3:** Metastasis of pigmented melanoma, with the presence of pleomorphic cells with invading gastric mucosa. Hematoxylin and eosin staining.

### Conflict of interest

The authors declare no conflicts of interest.

### REFERENCES

1. Carne JQ, Landim MR, Rodrigues M. Gastric metastatic melanoma. Case report. *Rev Bras Clin Med*. 2010;8(5):461-3.
2. Rocha ME, Rodrigues GP, Borges SA, Santiago FG. Metastatic Melanoma of the Stomach. *ABCD Arq Bras Cir Dig*. 2008;21(4):205-7. <http://dx.doi.org/10.1590/S0102-67202008000400010>.
3. Cardoso FS, Horta DV. Malignant melanoma metastasized in the stomach. *J Port Gastroenterology*. 2013;20(6):275-6.
4. Grander LC, Cabral F, Lisboa AP, Vale G, Barcaui CB, Maceira JM. Multiple cutaneous melanomas associated with gastric and brain. *An Bras Dermatol*. 2016;91(5 suppl 1):98-100. <http://dx.doi.org/10.1590/abd1806-4841.20164374>. PMID:28300909.
5. Queiroz CAS, Soares RH, Andrade LP, Viana MRS, Junior JAT, Silva JHA, et al. Gastric metastasis of malignant melanoma. *Rev Medica Minas Gerais*. 2017;21:898.

Received: Apr 7, 2019

Accepted: Jun 3, 2019