

## Calcinosis Cutis with Large Extension and Uncommon Location in a Dog

Reiner Silveira de Moraes<sup>1</sup>, Alana Flávia Romani<sup>2</sup>, Andréia Vitor Couto do Amaral<sup>2</sup>, Didier Quevedo Cagnini<sup>3</sup>,  
Leuton Scharles Bonfim<sup>1</sup> & Mariana Moreira Andraschko<sup>4</sup>

### ABSTRACT

**Background:** Calcinosis cutis is an uncommon dermatopathy characterized by the deposition of minerals in the skin, usually involving collagen and elastic fibers in the dermis. Usually, it results from dystrophic calcification and can be generalized or focal. The dermatopathy may be primary or secondary to certain disorders, especially chronic proliferative otitis, foreign body reactions, hyperadrenocorticism (HAC) and less frequently percutaneous penetration of calcium-rich products. The aim of this report is to describe a presentation of calcinosis cutis affecting the skin of the back, internal face of hind limbs and anal region of a 9-years-old bitch.

**Case:** A 9-year-old, non-defined breed, bitch, ovariohysterectomized, weighing 9.45 kg, was attended at the Dermatological Service of companion animals at the Veterinary Hospital of the Federal University of Jataí (UFJ). The animal came in with the complaint of extensive dorsal alopecia, covered by firm lesions, with a 3-month evolution, additionally to polyuria and polydipsia. After physical examination, alopecic areas of great extension were confirmed on the dorsum, on the internal surface of the hind limbs and in the anal region. Also, an exudative and painful lesion located on the back was detected, plus loss of elasticity of the ventral abdomen skin and visible abdominal vessels. The screening tests showed a marked increase in the alanine aminotransferase enzyme (ALT), alkaline phosphatase (ALP) and total cholesterol. The specific urinary density was decreased. On the ultrasound examination, hepatomegaly and an increase in the caudal pole of the left adrenal were detected. Based on these findings, calcinosis cutis secondary to spontaneous hyperadrenocorticism (HAC) was suspected. For confirmation, skin biopsy and low dose dexamethasone suppression test (LDDS) were performed. LDDS test showed no reduction of serum cortisol after 8 h of dexamethasone dose administration and histopathological evaluation revealed multiple foci of calcinosis characterized by the deposition of basophilic material on the pre-existing collagen fibers, plus areas with pyogranulomatous inflammatory reaction and peripheral fibrosis with transepidermal elimination of minerals. Thus, trilostane and intense hydration of skin plaques were applied as treatment.

**Discussion:** The dermatological alterations were compatible with those described in the consulted literature, with remarkable yellow-brown, firm, sandy-looking plaques, located on the back, internal face of hind limbs and anal region, possibly related to HAC later confirmed by LDDS test and biopsy. The management of the underlying disease and possible secondary bacterial infections are the basis of the treatment. Therefore, the patient was treated with trilostane, antibiotic therapy and intensive hydration of the mineralized plaques resulting in a satisfactory involution of the clinical signs. Even though there are reports of calcinosis cutis on the dorsum, in the consulted literature there was no evidence of dorsum large extension lesion due to HAC as in this case report, but secondary to exogenous corticosteroid treatment, systemic blastomycosis and leptospirosis. In this case report, the affected thorax portion was the dorsum, differently from a study that pointed the ventral thorax as the affected portion. Similarly, anus and ventral part of the tail were hardly affected together with secondary inflammation and ulceration. Thus, the existent literature shows areas of calcinosis cutis in dogs in different parts of the body, but neither extensive as in the back of this reported female dog, nor widely affected as in the anal area, additionally to the internal face of hind limbs as already reported in the literature.

**Keywords:** calcium, dermis, hyperadrenocorticism, precipitation.

DOI: 10.22456/1679-9216.106730

Received: 24 August 2020  
Published: 19 January 2021

Accepted: 10 December 2020

<sup>1</sup>Veterinarian, Veterinary Hospital; <sup>2</sup>Veterinary Medicine Department & <sup>3</sup>Biological Sciences Institute of Universidade Federal de Jataí (UFJ), Jataí, GO, Brazil. <sup>4</sup>Autonomous Veterinarian at the Veterinary Specialties Consultory (CEIV), Goiânia, GO. CORRESPONDENCE: R.S Moraes [rmoraes@ualberta.ca]. Medicina Veterinária, Hospital Veterinário - UFJ, Campus Jatobá. BR 364, km 195 n. 3800. CEP 75801-615 Jataí, GO, Brazil.

## INTRODUCTION

Calcinosis cutis is an uncommon dermatological alteration in dogs, in which insoluble mineral salts, such as calcium and phosphate are deposited in the dermis, subcutaneously and, more rarely, epidermis [7]. Mineral precipitation commonly affects collagen and elastic fibers in the dermis [13]. The occurrence generally results from dystrophic calcification and can occur in a generalized or localized manner [2]. The alteration may be primary or secondary to certain disorders, especially chronic proliferative otitis, foreign body reactions and hyperadrenocorticism (HAC) [1]. Less frequently, calcinosis cutis has been associated with percutaneous penetration of calcium-rich products [11] or as secondary to severe systemic diseases [2,6,10].

In dogs, dystrophic calcification usually occurs with hyperglucocorticoidism as calcinosis cutis, or as a result of focal trauma as calcinosis circumscripta [3]. Calcinosis cutis due to primary HAC has a high correlation with the average age of diagnosed patients, which varies from 9 to 11 years [1]. On the other hand, no sex predilections have been reported [3]. Clinically, calcinosis characterizes an isolated to multicentric, firm, erythematous and painful papules, nodules or plaques which can become ulcerated or crusted [9]. Skin points susceptible to repetitive flexure are more likely to the occurrence of calcinosis cutis, such as flexural surfaces of the groin, back of the neck and axillae [3].

The aim of this report is to describe a case of calcinosis cutis in a 9-years-old bitch with coalescing erythematous papules affecting the skin of the back, the internal face of hind limbs and anal region.

## CASE

A 9-year-old, non-defined breed bitch, ovariohysterectomized, weighing 9.45 kg, was attended at the Dermatological Service of companion animals at the Veterinary Hospital of the Federal University of Jataí (UFJ). The main complaint was the development of dorsal alopecia (Figure 1), covered by firm lesions, with a three-month evolution and the recent appearance of wet and painful lesions in the region. When asked, the pet owner reported that in the last few months the patient had lost weight, despite having her appetite preserved. The owner also mentioned that the animal had polyuria and polydipsia. According to him, no medication had been administered.

On the physical examination, there was evident muscular atrophy, especially in the temporal region and on the spine. In the dermatological inspection, alopecic areas of great extension were observed on the dorsum, on the internal surface of the hind limbs and in the anal area. In these areas, there were erythematous plaques with mineral deposition (Figure 2). The fur adjacent to these areas was opaque, dry and easily removable. In addition, an exudative and painful lesion located on the back was detected during examination. The skin of the ventral abdomen was thin, with loss of elasticity and visible abdominal vessels.

Among the laboratory changes detected in the screening tests, there was a marked increase in the alanine aminotransferase enzyme (450 IU/L) and alkaline phosphatase (2,800 IU/L), in addition to increased total cholesterol (350 mg/dL). Triglycerides and HDL cholesterol were within normal values. The urinary density resulted in 1,011. On the ultrasound examination, hepatomegaly and an increase in the caudal pole of the left adrenal (0.83 cm) were detected.

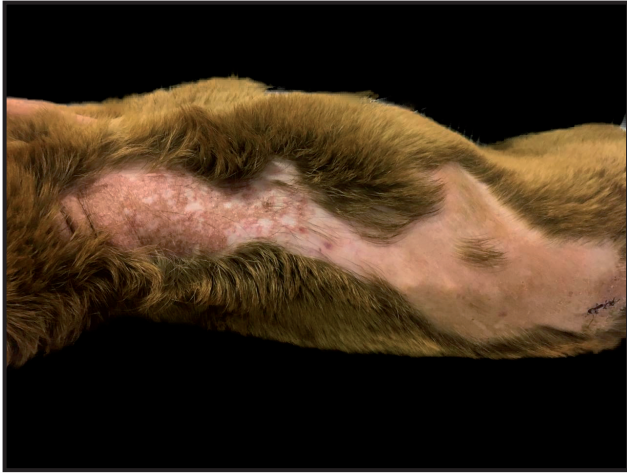As for the complementary dermatological evaluation, both parasitological tests such as, skin scraping and mycological tests were negative. In the cytological evaluation of the exudative lesion, squamous epithelial cells and a moderate presence of leukocytes infiltrate (predominantly neutrophils) and coccus bacteria were observed, indicating secondary bacterial infection of the plaques.

In view of the clinical and laboratory findings, the suspected diagnosis was calcinosis cutis secondary to spontaneous hyperadrenocorticism (HAC). For confirmation, skin biopsy and low dose dexamethasone suppression test - LDDS (SNAP® Cortisol Test)<sup>1</sup> were performed, with cortisol measured by the radioimmunoassay technique (RIA), as recommended by Herrtage & Ramsey [4].

Two wedge specimens of skin were collected from better-preserved lesions through punch biopsy<sup>2</sup> (4 mm) and fixed in 10% buffered-formaldehyde solution. Four micrometers cuts were performed using a mechanical rotating microtome (RM 2245)<sup>3</sup>, arranged in histological slides, and stained with hematoxylin<sup>4</sup> and eosin<sup>5</sup>. The slides were evaluated in light microscopy (O400S opticam)<sup>6</sup>. Grossly, the samples showed irregular, firm, yellowish-tan, gritty material. Microscopically, there were dermal deposition of multifocal, basophilic-intense material (mineral), sometimes associated with



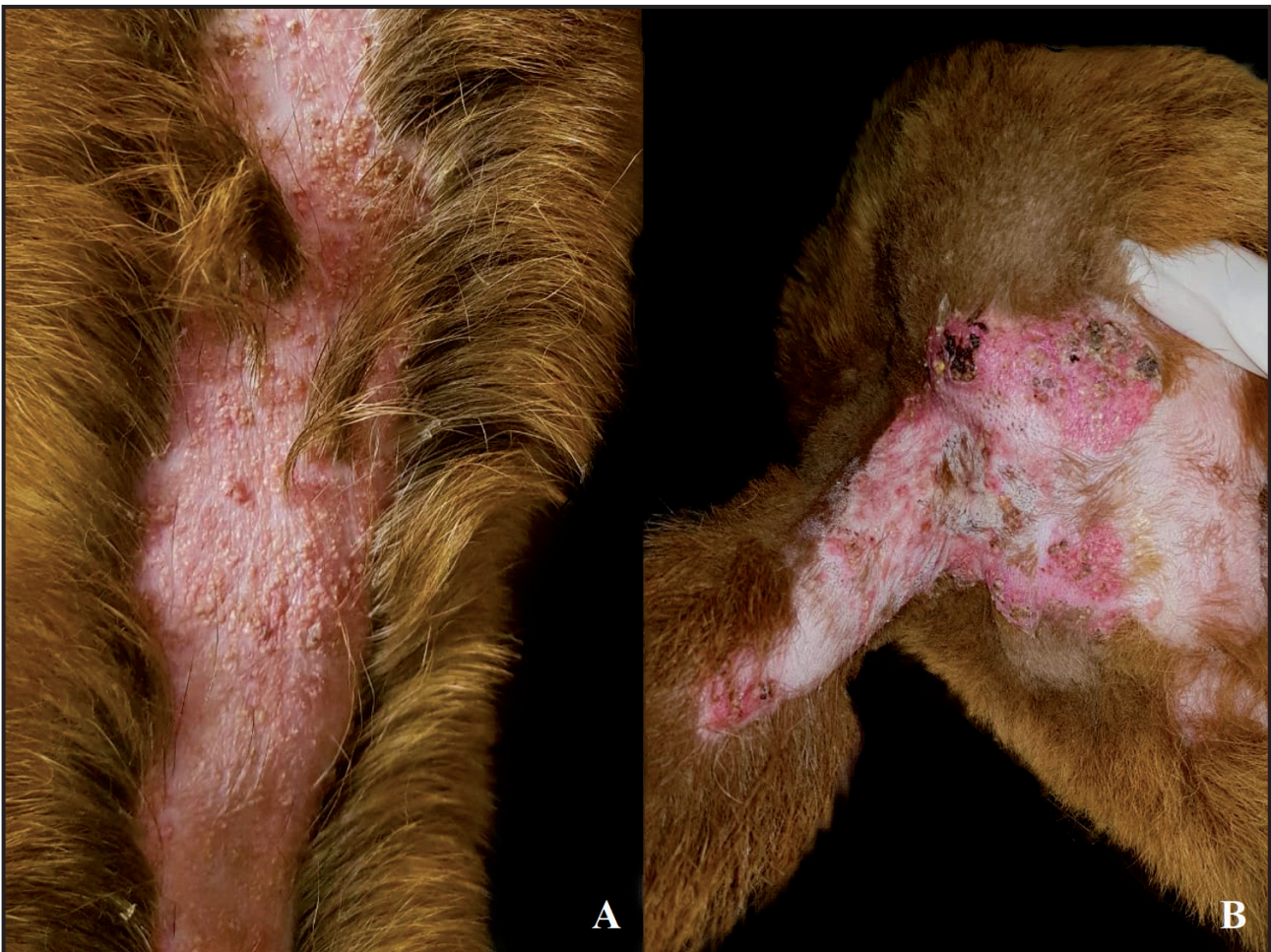pyogranulomatous inflammation and perilesional fibrosis. Furthermore, epidermis reveals transepidermal elimination of mineral and mild pyogranulomatous inflammatory reaction. Together, the findings led to the final diagnosis of calcinosis cutis (Figure 3).



**Figure 1.** Dog, skin, dorsal view, Calcinosis cutis. Alopecia throughout this region with coalescent, firm, yellowish-tan papules forming plaques with gritty material mainly located at the thorax.

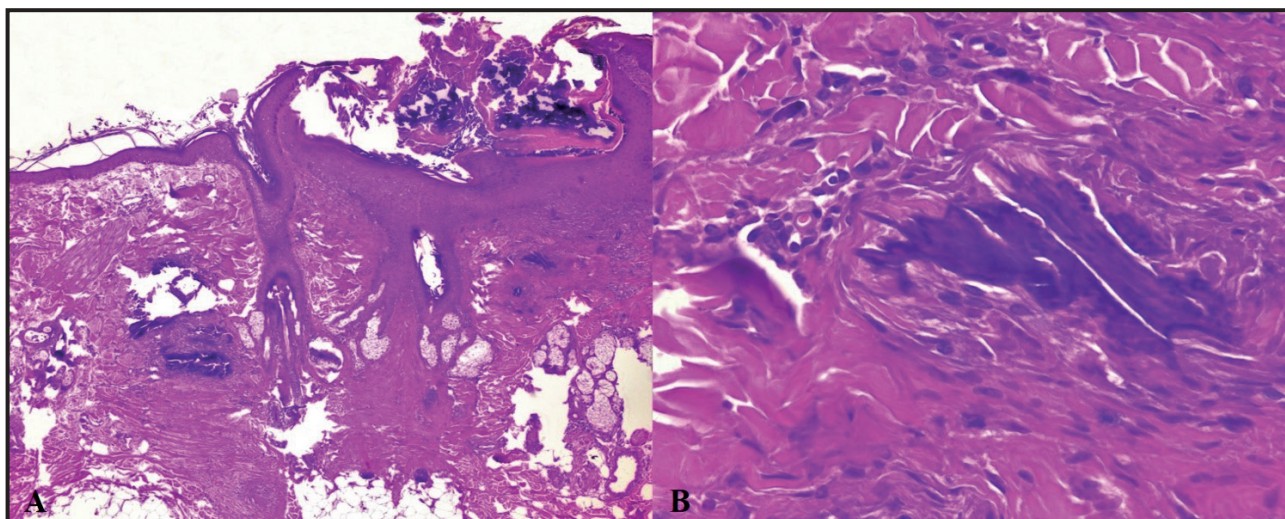
In order to perform the LDDS test, a blood sample was collected and centrifuged to obtain 1.0 mL of serum in which basal cortisol was measured, resulting in 6.79  $\mu\text{g/dL}$  (reference interval: 1.0 to 4.6  $\mu\text{g/dL}$ ). Then, 0.01 mg/kg of dexamethasone (Decadron®)<sup>7</sup> was intravenously administered. After 8 h, a new dosage of cortisol levels was carried out, resulting in 3.64  $\mu\text{g/dL}$  (reference interval: < 0.90  $\mu\text{g/dL}$ ). The LDDS test confirmed HAC because it did not reveal suppression of cortisol 8 h after the application of the glucocorticoid.

After confirmation of the diagnosis of HAC, treatment with trilostane (Vetoryl®)<sup>8</sup> was applied at a dosage of 0.5 mg/kg in each 12 h, with dose adjustments every 21 days in order to minimize the chances of side effects. Amoxicillin with clavulanic acid (Age-moxi CL®)<sup>9</sup> at a dose of 25 mg/kg in each 12 h for 21 days was used to control secondary bacterial infection. Also, topic treatment with moisturizing baths and antiseptic spray twice a week were considered. The antiseptic spray was manipulated with chlorhexidine



**Figure 2.** Dog, skin, Calcinosis cutis. A- Approximated view of dorsal thoracic lesions presenting irregular papules and plaques. B- Skin, hind limbs, anus, and tail regions with plaques showing redness and crust due to secondary inflammation and ulceration.





**Figure 3.** Skin biopsy of a dog: diagnosis of calcinosis cutis. A- Multifocal deposition of basophilic-intense material (mineral) in dermis. Note the extrusion of mineral through the epidermis, characterizing the transepidermal (transepithelial) elimination [HE; 400x]. B- Detail of dermal mineral deposition surrounded by fibrous tissue [HE; 400x].

4%, hydroviton 4% and aqueous solution<sup>10</sup>. Plus, the application of oily lotion (Dersani®)<sup>11</sup> in every 12 h composed of essential fatty acids, medium chain triglycerides and vitamins A and E. Two weeks after the onset of the treatment, there was a clinical resolution of the secondary infection, in addition to an initial improvement in calcinosis cutis and signs of HAC.

#### DISCUSSION

Calcinosis cutis is an uncommon dermatological alteration, usually secondary to other disorders [1,7]. Considering the correlation with HAC, especially in animals between 9 and 11 years old, the patient in this report fits in, reinforcing the age target when it comes to calcinosis cutis [1,8,14]. In this case report, calcinosis cutis reached large proportions and was accompanied by clinical signs suggestive of endocrinopathy, such as alopecia, muscular atrophy, thin skin, polyuria and polydipsia. The dermatological alterations were compatible with those described in the consulted literature, with remarkable yellow-brown, firm, sandy-looking plaques, located on the back. The patient also developed well marked inflammatory plaques in the perineal region and internal face of hind limbs, as a possible syndrome related to HAC [5].

The screening tests reinforced the suspicion of HAC, which could be confirmed by the technique recommended by Herrtage & Ramsey [4]. To perform skin biopsy, the areas of preference were those calcified without concurrent occurrence of trauma or ulceration, following recommendations [3]. The macroscopic and microscopic characteristics were compatible with those

described by the mentioned authors, thus confirming the diagnosis of calcinosis cutis.

Microscopically, the differential diagnosis is simple if mineralization is obvious in tissue as it was in the present case [3]. In early lesions, when mineralization is not evident, Von Kossa staining may aid to the diagnosis as the presence of fractured collagen fibers. Calcinosis circumscripta is characterized by large focal or multifocal masses, which is highly different from calcinosis cutis pattern [1]. Another type of mineralization, as metastatic, could be easily differentiated from calcinosis cutis, since the first was secondary to elevated calcium levels in the blood, associated with chronic kidney disease and is manifested as calcinosis circumscripta [3,10].

The management of the underlying disease and possible secondary bacterial infections are the basis of treatment [12]. Thus, the patient was treated with trilostane, antibiotic therapy and intensive hydration of the mineralized plaques resulting in a satisfactory involution of the clinical signs.

Even though, there are reports of calcinosis cutis on the dorsum, in the consulted literature there was no evidence of dorsum large extension lesion due to HAC, but secondary to exogenous corticosteroid treatment, systemic blastomycosis and leptospirosis [2,7,10]. Lesions are usually described as multiple lesions distributed in areas such as flank, axilla, ventral thorax, extremities, inguinal region, head and perigenital region [1]. In this case report, the thorax portion affected was the dorsum, differently from that related in the aforementioned study. Similarly, anus and ventral part of the tail were affected together with secondary inflammation and ulceration as previously shown.

A study did not demonstrate the spreading of calcinosis cutis on the dorsum as in the actual case, highlighting lesions on the ventral abdomen and inguinal region as a result of percutaneous penetration of calcium carbonate [11]. Another study did not find calcinosis cutis secondary to HAC in 10 investigated dogs, but extended lesion originated from bacterial infections [14]. In an analysis of 46 cases of calcinosis cutis, the endogenous HAC showed to be the primary cause of dermatological alteration on the dorsum given as the most affected area, therefore, no data on the extension of these lesions was provided, giving this case report a highlight.

#### MANUFACTURERS

<sup>1</sup>IDEXX Brasil Laboratórios Ltda. São Paulo, SP, Brazil.

<sup>2</sup>Paramount Surgimed Ltda. New Delhi, Delhi, India.

<sup>3</sup>Leica Biosystems Division of Leica Microsystems Inc. Buffalo

Grove, IL, USA.

<sup>4</sup>Wcor Corantes Comercio e Servicos Eireli. Guarulhos, SP, Brazil.

<sup>5</sup>Vetec Química Fina Ltda. Rio de Janeiro, RJ, Brazil.

<sup>6</sup>Opticam Microscopy Technology. São Paulo, SP, Brazil.

<sup>7</sup>Novafarma - Indústria Farmacêutica Ltda. Anápolis, GO, Brazil.

<sup>8</sup>Bioctal - Comércio de Produtos Veterinários Ltda. Valinhos, SP, Brazil.

<sup>9</sup>Agener - União Saúde Animal - Farmacêutica Nacional S.A. São Paulo, SP, Brazil.

<sup>10</sup>ArtPharma - Fórmulas Oficinais Ltda. Jataí, GO, Brazil.

<sup>11</sup>Sanyplan Laboratórios Ltda. Rio de Janeiro, RJ, Brazil.

**Acknowledgments.** To the Veterinary Hospital (UFJ), the staff involved in collecting the specimens for histopathological analysis and the endocrinologist, Mariana Andraschko for the support. We also thank Dr. Fabrizio Grandi for providing the histopathological images.

**Declaration of interest.** The authors report no conflicts of interest. The authors alone are responsible for the content and writing of the paper.

#### REFERENCES

- 1 Doerr K.A., Outerbridge C.A., White S.D., Kass P.H., Shiraki R., Lam A.T. & Affolter V.K. 2013. Calcinosis cutis in dogs: histopathological and clinical analysis of 46 cases. *Veterinary Dermatology*. 24(3): 355-379.
- 2 Gortel K., McKiernan B.C., Johnson J.K. & Campbell K.L. 1999. Calcinosis cutis associated with blastomycosis in three dogs. *Journal of the American Animal Hospital Association*. 35(5): 368-374.
- 3 Gross T.L., Ihrke P.J., Walder E.J. & Affolter V.K. 2005. Degenerative, dysplastic and depositional diseases of dermal connective tissue. In: *Skin Diseases of the Dog and Cat: Clinical and Histopathologic Diagnosis*. 2nd edn. Hoboken: Blackwell, pp.373-404.
- 4 Herrtage M.E. & Ramsey I.K. 2012. Canine hyperadrenocorticism. In: Mooney C.T. & Peterson M.E. (Eds). *Manual of Canine and Feline Endocrinology*. 4th edn. Gloucester: British Small Animal Veterinary Association, pp.254-289.
- 5 Hnilica K.A. & Patterson A.P. 2016. *Small Animal Dermatology: A Colour Atlas and Therapeutic Guide*. 4th edn. St. Louis: Elsevier, 652p.
- 6 Holahan M.L., Loft K.E., Swenson C.L. & Martinez-Ruzafa I. 2008. Generalized calcinosis cutis associated with disseminated paecilomycosis in a dog. *Veterinary Dermatology*. 19(6): 368-372.
- 7 Hsu K., Snead E., Davies J. & Carr A. 2012. Iatrogenic hyperadrenocorticism, calcinosis cutis, and myocardial infarction in a dog treated for IMT. *Journal of the American Animal Hospital Association*. 48(3): 209-215.
- 8 Martins F.S.M., Carvalho G.L.C., Jesus L., Pöpl A.G. & González F.H.D. 2019. Epidemiological, clinical, and laboratorial aspects in a case series of canine hyperadrenocorticism: 115 cases (2010-2014). *Brazilian Journal of Veterinary Research*. 39(11): 900-908.
- 9 Muller A., Degorce-Rubiales F. & Guaguerè E. 2011. Metastatic calcinosis (including calcinosis cutis) in a young dog with multiple urinary tract abnormalities. *Veterinary Dermatology*. 22(3): 279-283.
- 10 Munday J.S., Bergen D.J. & Roe W.D. 2005. Generalized calcinosis associated with probable leptospirosis in a dog. *Veterinary Dermatology*. 16(6): 401-406.
- 11 Paradis M. & Scott D.W. 1989. Calcinosis cutis secondary to percutaneous penetration of calcium carbonate in a Dalmatian. *The Canadian Veterinary Journal*. 30(1): 57-59.
- 12 Tolon J.M.C., Jimenez J.J.E., Irizar I.G. & Trasobares P.C. 2018. Resolution of iatrogenic calcinosis in a dog through topical application of DMSO. *Veterinary Record Case Reports*. 6(3): 1-2.
- 13 Walsh J.S. & Fairley J.A. 1995. Calcifying disorders of the skin. *Journal of the American Academy of Dermatology*. 33(5): 693-706.
- 14 Zur G. & White S.D. 2011. Hyperadrenocorticism in 10 Dogs with Skin Lesion as the Only Presenting Clinical Signs. *Journal of the American Animal Hospital Association*. 47(6): 419-427.