

Caseous Stomatitis Caused by *Pseudomonas aeruginosa* in *Boa constrictor amarali*

Nathana Beatriz Martins¹, Lucas Arthur Ricardo Ferreira¹, Caroline Lopes Queiroz²,
Ana Beatriz Garcez Buiatte², Anna Monteiro Correia Lima², Rafael Rocha de Souza¹,
Wilson Junior Oliveira² & André Luiz Quagliatto Santos¹

ABSTRACT

Background: *Pseudomonas aeruginosa* is a bacterium that belongs to the microbiota of snakes, but it may also be an opportunistic pathogen and contaminate humans through fecal contact, bites, and injuries. In snakes, this microorganism may present high pathogenicity at certain conditions and have been associated with high morbidity and mortality. Reports of infection of *Boa constrictor* by this pathogen are rare. Thus, this study aimed to describe the *P. aeruginosa* oral infection in a snake specimen (*Boa constrictor amarali*), approaching the isolation and identification of the infectious agents involved, the antimicrobial sensitivity and resistance, and the therapeutic protocol adopted.

Case: A free-living adult female specimen of *Boa constrictor amarali* (Amaral's boa), with no described previous history was rescued in an urban area by the Environmental Police. Clinical evaluations showed structures of caseous aspect in the oral cavity, with hyperemia spots in the mucosa. Samples of these lesions were sent for mycological examination, and fungal forms were not found. Samples were collected for isolation and culture. The antimicrobial susceptibility of the isolated microorganisms was determined by the modified Kirby-Bauer disk diffusion method. *P. aeruginosa* was isolated and showed susceptibility to amikacin, gentamicin, and polymyxin-B; intermediate susceptibility to azithromycin, and ciprofloxacin; and resistance to cephalexin, ceftiofur, chloramphenicol, and enrofloxacin. The treatment consisted of cleaning of the oral cavity, local infiltration of lidocaine for debridement of the caseous area that were later cauterized with iodine. Systemic antibiotic therapy was used, with intramuscular administration of amikacin (5 mg/kg) for the first dose and (2.5 mg/kg) for the other doses with intervals of 72 h, and oral administration of metronidazole (20 mg/kg) with intervals of 48 h, both during 21 days. Daily subcutaneous fluid therapy was performed as support treatment, using Lactated Ringer's solution (25 mg/kg) and Vitamin C (10 mg/kg) with intervals of 24 h, being the cure observed at the end of treatment.

Discussion: This paper presents the pathological findings of the *Pseudomonas aeruginosa* oral infection in a *B. constrictor amarali*. This bacterium is an opportunistic pathogen that is commonly found in snakes, thus, humans in contact with these animals may be contaminated with this pathogen. However, oral cavity lesions associated with *P. aeruginosa* had not yet been related to *Boa constrictor amarali*, which is a non-venomous species. Few bacteria associated with reptile diseases are primary causative agents. Clinical bacterial infections generally tend to be secondary to viral infections. Predisposing factors for the development of bacterial diseases in these reptiles include immunodepression, malnutrition, poor adaptation to captivity, and the maintenance of these animals at temperatures and humidities outside their thermal comfort range. In the present study, the *P. aeruginosa* behaved as an opportunistic pathogen, resulting in clinical manifestations with caseous lesions in the oral cavity, probably due to an imbalance of the microbiota caused by stress or immunodepression. The antibiogram allowed the adoption of a correct therapeutic protocol based on the susceptibility of the pathogen, resulting in remission of lesions and clinical signs after 21 days of treatment.

Keywords: abscesses, bacteriosis, infectious diseases, snakes.

DOI: 10.22456/1679-9216.105257

Received: 15 August 2020

Accepted: 26 January 2021

Published: 12 March 2021

¹Laboratório de Ensino e Pesquisa em Animais Silvestres (LAPAS) & ²Laboratório de Doenças Infecto-contagiosas (LADOC), Faculdade de Medicina Veterinária (FAMEV), Universidade Federal de Uberlândia (UFU), Uberlândia, MG, Brazil. CORRESPONDENCE: R.R. Souza [rafael.souza@ufu.br]. Faculdade de Medicina Veterinária (FAMEV) - UFU. Av. Mato Grosso n. 3289 - Bloco 2S. CEP 38405-314 Uberlândia, MG, Brazil.

INTRODUCTION

Boa constrictor amarali is a non-venomous snake of the Squamata order (Ophidia suborder) that is widely distributed in the Brazilian territory [9], especially in the Northeast, Southeast, and South regions [7].

Infectious diseases are the main causes of mortality of snakes, mainly by Gram negative microorganisms. The predominance of these bacteria in infectious processes is directly connected to the opportunistic character of the normal bacterial microbiota of the host, especially in infections caused by *Pseudomonas* sp., *Aeromonas hydrophila*, *Proteus* sp., *Salmonella* sp., *Citrobacter* sp., *Escherichia coli*, *Providencia* sp. and *Xanthomonas maltophilia* [9].

Reptiles host important zoonotic microorganisms, such as the bacterium *Pseudomonas aeruginosa*, therefore, humans can be contaminated with these microorganisms through fecal contact, bites, and injuries [4]. *Pseudomonas* spp. may present high pathogenicity at certain conditions and have been associated with high morbidity and mortality in infected animals due to their ability to develop resistance to antibiotics and express multiple virulence factors [14].

P. aeruginosa can be isolated from samples of diseased and healthy reptiles. The first cases of cross contamination between snakes and their healthy owners have been reported recently [1]. *P. aeruginosa* is a microorganism that belongs to the microbiota of reptiles, especially in their oral cavity and intestinal tract; however, it can be an opportunistic pathogen with several clinical manifestations in susceptible animals [2].

CASE

A free-living adult female specimen of *Boa constrictor amarali* (Amaral's boa), with no described previous history was rescued in an urban area by the Environmental Police and taken to the Laboratory of Teaching and Research in Wild Animals of the Veterinary Hospital of the Federal University of Uberlândia (VH-UFU), Minas Gerais, Brazil. The animal was weighed in a digital scale and presented 3.2 kg.

The clinical evaluation showed dehydration signs, and presence of caseous structures in the oral cavity, in the upper-left, upper-right, and lower-right tooth regions, with hyperemia spots in the mucosa (Figure 1A). Samples of these lesions were collected

and sent to the Veterinary Clinical Laboratory of the VH-UFU for mycological examination. This material was placed in slides and analyzed in an optical light microscope (10x and 40x objective) using tow drops of 10% potassium hydroxide (Anidrol®)¹ to clear the sample, but fungal forms were not found.

Samples were collected by passing a sterilized alginate cotton tip swab through the entire lesion. The sample was stored in a plastic tube containing a semi-solid transport medium Stuart (Absorve®)² and sent to the Laboratory of Infectious Diseases of UFU. The sample was then transferred to a tube containing Thioglycollate broth (Himedia®)³ - a highly nutritive medium that helps the growth of microorganisms - and incubated in a bacteriological oven at 37°C for 24 h [12].

Samples were plated for bacterial isolation on one Petri dish containing blood agar and other containing MacConkey agar (TM Media®)⁴, using the streaking technique with a platinum inoculating loop. These dishes were placed in a bacteriological oven at 37°C for 24 h for incubation [16]. Gram staining was carried out to identify gram-positive and gram-negative bacteria in the blood agar (Kasvi®)⁵ colonies.

Colonies grown on MacConkey4 agar were identified through biochemical tests in the mediums phenol red, lysine, phenylalanine, citrate, urea, and SIM (sulfide, indole, motility), screening colonies that grow on selective medium for gram-negative bacteria of the Enterobacteriaceae family. A medium was used for each different colony grown on MacConkey⁴ agar to identify each bacterial genus or species. The oxidation-fermentation test was included for colonies of gram-negative bacteria that were not of the Enterobacteriaceae family.

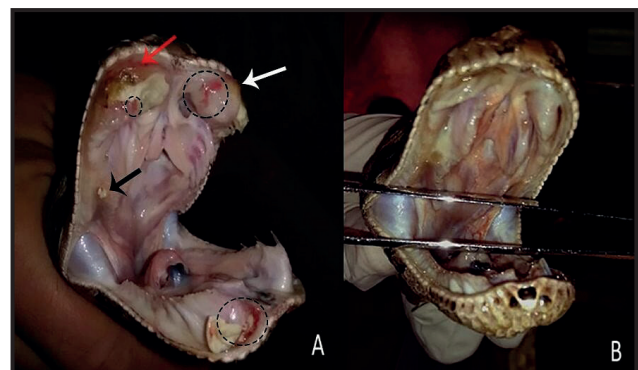


Figure 1. Oral cavity of a specimen of *Boa constrictor amarali* with caseous stomatitis. A- Presence of caseous structures in the upper-left (white arrow), upper-right (red arrow), and lower-right (black arrow) tooth regions, with hyperemia spots in the mucosa (circles). B- Absence of caseous lesions and hyperemia spots in the mucosa after 21 days of treatment.

Colonies of *Pseudomonas* spp. grew on MacConkey agar medium⁴; these bacteria were identified by their colony morphology and typical odor. Biochemical tests confirmed this genus and identified the bacterium species *Pseudomonas aeruginosa*.

The antimicrobial susceptibility of the isolated microorganisms was determined by the modified Kirby-Bauer disk diffusion method [12]. The isolates were inoculated in Mueller Hinton (Kasvi®)⁵ broth and incubated at 37°C until showing turbidity of 0.5 according to the Mac Farland scale. The isolates were streaked on Petri dishes containing Muller Hinton agar medium, using a swab. Subsequently, the antimicrobial drugs enrofloxacin, ciprofloxacin, amikacin, ceftiofur, gentamicin, chloramphenicol, azithromycin, polymyxin-B, and cephalixin (Laborclin®)⁶ were applied to the impregnated discs [9]. They were then incubated in an oven at 37°C for 24 h and the formed halos were evaluated to determine the susceptibility profile of the isolated pathogens.

P. aeruginosa presented susceptibility to amikacin, gentamicin, and polymyxin-B; intermediate susceptibility to azithromycin, and ciprofloxacin; and resistance to cephalixin, ceftiofur, chloramphenicol, and enrofloxacin.

The treatment consisted of cleaning of the oral cavity with 0.9% saline solution (0.9% Saline)⁷ and oral 2.0% chlorhexidine (Riohex®)⁸, local infiltration of 2.0% lidocaine (Xylestesin®)⁹ for debridement of the caseous lesions, and cauterization of the lesions with iodine (Riodeine®)⁸. Local cleaning and cauterization with iodine were performed daily at lesion sites.

Based on the antimicrobial susceptibility testing (AST) and according to Klaphake [8], amikacin (Amicilon®)¹⁰ was administered intramuscularly (5 mg/kg) for the first dose and 2.5 mg/kg for the other doses with intervals of 72 h, combined with oral administration of metronidazole [Benzoilmetronidazol¹¹ at dose of 20 mg/kg with intervals of 48 h], both during 21 days. Metronidazole¹¹ can be given simultaneously with amikacin¹⁰ for a larger spectrum.

Daily subcutaneous fluid therapy was performed as support treatment, using Lactated Ringer's⁹ solution (25 mg/kg) and Vitamin C [Monovin C®¹² - 10 mg/kg] with intervals of 24 h [8]. Vitamin C can be a coadjuvant in cases of stomatitis and cutaneous conditions, and a supportive therapy for bacterial

infections. Remission of lesions and clinical signs was observed after 21 days of treatment (Figure 1B).

The animal remained under controlled temperature of 30°C throughout the treatment for better metabolism of the drugs.

DISCUSSION

Infectious agents can be transmitted to snakes through wounds caused by trauma, and contact with contaminated environments, handlers, and utensils. However, immunodepression, malnutrition, poor adaptation to captivity, and the maintenance of these animals at temperatures and humidities outside their thermal comfort range are considered predisposing factors for the development of bacterial diseases in these reptiles [15]. However, few bacteria associated with reptile diseases are primary causative agents. Clinical bacterial infections generally tend to be secondary to viral infections [8].

Pseudomonas spp. belong to the microbiota of snakes, especially in their oral cavity [4,6,17]. However, in conditions of high pathogenicity, clinical manifestations and lesions can develop in their oral cavity and even in other organs [4,11,18]. In the present study, the *P. aeruginosa* behaved as an opportunistic pathogen, resulting in clinical manifestations with caseous lesions in the oral cavity, probably due to an imbalance of the microbiota caused by stress or immunodepression.

P. aeruginosa has been isolated from skin vesicles of a coral snake (*Micrurus corallinus*), scales with caseous content of a sური snake (*Eunectes murinus*) [5], and subcutaneous nodules of a boa snake (*Boa constrictor amarali*) [11]. However, oral cavity lesions associated with *P. aeruginosa* had not yet been related to *Boa constrictor amarali*, which is a non-venomous species.

P. aeruginosa is an opportunistic pathogen for animals and humans, associated with high morbidity and, sometimes, high mortality. Studies have shown that captive reptiles have been carriers of *P. aeruginosa*, thus, they are sources of contaminations for humans who interact with these animals [3,4].

P. aeruginosa from skin lesions of snakes was isolated in previous studies and was observed resistance to all antibiotics tested in the AST; even with the establishment of systemic and topical antibiotic therapy, 90.9% of the animals died, denoting the multiresistance of the isolated agents [5]. Cases

of multiresistant bacteria isolated from reptiles has been reported [11,13,19], showing the limitation of the therapeutic protocols adopted [5] and the need of AST to determine the susceptibility or resistance profile of these agents to avoid resistances to antimicrobials.

In the present study, the pathogen evaluated was not resistant to all antimicrobials tested, but it was resistant to cephalixin, ceftiofur, chloramphenicol and enrofloxacin; moderately resistant to azithromycin, and ciprofloxacin; and susceptible to amikacin, gentamicin, and polymyxin-B. The AST allowed the adoption of a correct therapeutic protocol, based on the susceptibility of the microorganism, resulting in remission of lesions and clinical signs after 21 days of treatment.

MANUFACTURERS

- ¹Anidrol Produtos para Laboratórios Ltda. Diadema, SP, Brazil.
- ²CRAL Artigos para Laboratório Ltda. Cotia, SP, Brazil.
- ³Himedia Laboratories Private Ltd. Mumbai, MM, India.
- ⁴Titan Biotech Ltd. Delhi, TCN, India.
- ⁵Kasvi Produtos Laboratoriais. São José do Pinhais, PR, Brazil.
- ⁶Laborclin Produtos para Laboratórios Ltda. Pinhais, PR, Brazil.
- ⁷Eurofarma Laboratórios S.A. Itapevi, SP, Brazil.
- ⁸Rioquímica Indústria Farmacêutica. São José do Rio Preto, SP, Brazil.
- ⁹Cristália Produtos Químicos e Farmacêuticos Ltda. Itapira, SP, Brazil.
- ¹⁰Blau Farmacêutica S.A. Cotia, SP, Brazil.
- ¹¹Laboratório Teuto Brasileiro. Anápolis, GO, Brazil.
- ¹²Laboratório Bravet Ltda. Engenho Novo, RJ, Brazil.

Declaration of interest. The authors report no conflicts of interest. The authors alone are responsible for the content and writing of the paper.

REFERENCES

- 1 **Colinon C., Jocktane D., Brothier E., Rossolini G.M., Cournoyer B. & Nazaret S. 2010.** Genetic analyses of *Pseudomonas aeruginosa* isolated from healthy captive snakes: evidence of high inter-and intrasite dissemination and occurrence of antibiotic resistance genes. *Environmental Microbiology*. 12(3): 716-729.
- 2 **Cushing A., Pinborough M. & Stanford M. 2011.** Review of bacterial and fungal culture and sensitivity results from reptilian samples submitted to a UK laboratory. *Veterinary Record*. 169(15): 390.
- 3 **Ebani V.V., Fratini F., Ampola M., Rizzo E., Cerri D. & Andreani E. 2008.** *Pseudomonas* and *Aeromonas* isolates from domestic reptiles and study of their antimicrobial *in vitro* sensitivity. *Veterinary research communications*. 32(1): 195-198.
- 4 **Ferreira Jr. R.S., Siqueira A.K., Campagner T.S., Salermo T., Soares T.C.S., Lucheis S.B. & Barraviera B. 2009.** Comparison of wildlife and captivity rattlesnakes (*Crotalus durissus terrificus*) microbiota. *Pesquisa Veterinária Brasileira*. 29(12): 999-1003.
- 5 **Ferreira P.R.B., Curvelo V.P., Gondim L.Q.S., Santana G.O. & Oliveira A.V.D. 2014.** Sinais clínicos e alterações necroscópicas em filhotes de *Eunectes murinus* (Linnaeus, 1758) infectados com bactérias Gram negativas multiresistentes. *Jornal Brasileiro de Ciência Animal*. 7(14): 508-522.
- 6 **Fonseca M.G., Moreira W.M.Q., Cunha K.C., Ribeiro A.C.M.G. & Almeida M.T.G. 2008.** Oral Microbiota of Brazilian Captive Snakes. *Journal of Venomous Animal and Toxins Including Tropical Diseases*. 15(1): 54-60.
- 7 **Giant constrictors: biological and management profiles and an establishment risk assessment for nine large species of pythons, anacondas, and the Boa constrictor. 2009.** *US Geological Survey*, 186p. Disponível em: <<https://pubs.usgs.gov/of/2009/1202/pdf/OF09-1202.pdf>>
- 8 **Klaphake E., Gibbons P.M., Sladky K.K. & Carpenter J.W. 2018.** Reptiles. In: Carpenter J.W. (Ed). *Exotic Animal Formulary*. 5th edn. St Louis: Elsevier, pp.127-246.
- 9 **Kolesnikovas C.K.M., Greco K.F. & Rahme-de-Albuquerque L.C. 2014.** Répteis - Ordem Squamata - Subordem Ophidia. In: Cubas Z.S., Catão-Dias J.L. & Silva J.C.R (Eds). *Tratado de Animais Selvagens - Medicina Veterinária*. 2.ed. São Paulo: Roca Ltda., pp. 68-85.
- 10 **Liu D., Wilson C., Hearlson J., Singleton J., Thomas R.B. & Crupper S.S. 2013.** Prevalence of antibiotic-resistant Gram negative bacteria associated with the red-eared slider (*Trachemys scripta elegans*). *Journal Zoo and Wildlife Medicine*. 44: 666-671.
- 11 **Martins N.B., Ferreira L.A.R., Santos A.L.Q., Souza R.R., Oliveira W.J., Moreira T.A., Queiroz C.L. & Lima A.M.C. 2017.** Dermatopathy Caused by *Enterobacter aerogenes* and *Pseudomonas aeruginosa* in *Boa constrictor amarali*. *Acta Scientiae Veterinariae*. 45(1): 1-4.

- 12 Oplustil C.P., Zoccoli C.M., Tobouti N.R. & Sinto S.I. 2004. *Procedimentos Básicos em Microbiologia Clínica*. 2.ed. São Paulo: Sarvier, 340p.
- 13 O'Neill A.J. 2008. New antibacterial agents for treating infections caused by multi-drug resistant Gram negative bacteria. *Expert Opinion on Investigational Drugs*. 17: 297-302.
- 14 Palamthodi S.M., Gaikwad V.J., Ghasghase N.V. & Patil S.S. 2011. Antibacterial targets in *Pseudomonas aeruginosa*. *International Journal of Pharmacology*. 2(3): 159-164.
- 15 Paré J.A., Sigler L., Rosenthal K.L. & Mader D.R. 2006. Microbiology: fungal and bacterial diseases of reptiles. In: Mader D.R. (Ed). *Reptile Medicine and Surgery*. 2nd edn. St. Louis: Saunders Elsevier, pp.217-238.
- 16 Quinn L.M., Dickins R.A., Coombe M., Hime G.R., Bowtell D.D. & Richardson H. 2004. *Drosophila* Hfp negatively regulates dmyc and stg to inhibit cell proliferation. *Development*. 131(6): 1411-1423.
- 17 Shek K.C., Tsui K.L., Lam K.K., Crow P., Ng K.H., Ades G. & Lam T.S. 2009. Oral bacterial flora of the Chinese cobra (*Naja atra*) and bamboo pit viper (*Trimeresurus albolabris*) in Hong Kong SAR, China. *Hong Kong Medical Journal*. 15(3): 183-190.
- 18 Wernick M.B., Novo-Matos J., Ebling A., Kuhn K., Ruetten M., Hilbe M., Howard J., Chang R., Prohaska S. & Hatt J.M. 2015. Valvulopathy consistent with endocarditis in an argentine boa (*Boa constrictor occidentalis*). *Journal of Zoo and Wildlife Medicine*. 46(1): 124-129.
- 19 Zajac M., Wasyl D., Hoszowski A., Le Hello S. & Szulowski K. 2013. Genetic lineages of *Salmonella enterica* serovar Kentucky spreading in pet reptiles. *Veterinary Microbiology*. 166: 686-689.