

## Impact of Hypotensive Action of Angiotensin Converting Enzyme Inhibitor on Ovarian-Intraovarian Blood Flow and Follicles Development in Goats Hormonally Stimulated with Repeated FSH-ECG Treatment

Maria Eugenia Moreno, Pamela Angela Bravo, Denilsa Pires Fernandes, César Carneiro Linhares Fernandes, Rafael Rossetto, Camila Muniz Cavalcanti, Assis Rubens Montenegro, Dárcio Ítalo Alves Teixeira & Davide Rondina

### ABSTRACT

**Background:** Recent evidence shows that the renin-angiotensin system (RAS) participates in important reproductive processes, such as steroidogenesis, folliculogenesis, oocyte maturation and ovulation. Several studies have proposed to use an angiotensin-converting enzyme (ACE) as a RAS modulator, aiming to improve reproductive efficiency, however, the presence of the main components of this system in reproductive tissues still need to be further investigated, since the physiological functions seem to be species-specific. The aim of this study was to assess the impact of enalapril-maleate, an ACE inhibitor, during repeated gonadotropins treatment on ovarian blood flow and follicular development in goats.

**Materials, Methods & Results:** Twenty Anglo-Nubian cross-bred goats were equally grouped according to parity (n= 10/group): nulliparous and multiparous parity. In each group, five animals were randomly selected to receive 0.4 mg.kg<sup>-1</sup> of enalapril-maleate during 11 days of estrus synchronization and gonadotropins treatments. The other animals received the same volume of saline solution. Estrus synchronization of all goats was made by intramuscular administration of PGF<sub>2</sub> analog, followed 48 h later by intravaginal insertion of a controlled internal drug release device. Forty-eight h after device withdrawal, a single dose of 60 mg of FSH plus 300 UI of eCG was administered and repeated every 4 days to complete 3 treatments. Transrectal ultrasonography was performed using pulsed and color Doppler to evaluate Doppler velocimetric parameters of the ovarian artery and intraovarian blood flow, respectively, and B-mode real-time ultrasound scanner to evaluate the follicular development. In the females treated with enalapril-maleate was observed a significant reduction of systolic and diastolic peak, without difference according to parity. In addition, in the third session of hormonal stimulation, only the groups (nulliparous and multiparous) not treated with enalapril maleate had a significant increase in the intraovarian blood flow (Doppler area). In treated group was also found a greater number of small follicles, a lower proportion of follicle  $\geq 5$  mm and a smaller follicular size. In the same group, the nulliparous females had a lower proportion of large follicles compared to the saline group, otherwise, there were no differences between the treatments in multiparous goats. In the group treated with enalapril maleate, higher number of large follicles was observed in multiparous animals than in the nulliparous ones.

**Discussion:** *In vivo* and *in vitro* studies have shown clear effects of RAS modulation on re-productive aspects. Our results confirmed the hypotensive effect of enalapril maleate on the ovarian artery and intraovarian blood flow, also showing that the administration of the drug reduced the process of follicular depletion and the growth of large follicles. These findings suggest that the hypotensive effects observed in our experiment, result from the treatment with the ACE inhibitor, and that this alteration in hemodynamic parameters may be the main responsible for the lower follicular response observed in animals treated with enalapril-maleate. We suggest that further studies are necessary to elucidate possible effects of the administration of an ACE inhibitor on ovarian activity, especially in the expression of genes associated with follicular, oocyte and embryonic development. Finally, the study conclude that the administration of enalapril-maleate in our experimental condition exhibit a hypotensive effect on ovarian circulatory system but did not show to promote a real benefit of follicular development in goats.

**Keywords:** Doppler, goats, ovarian stimulation, renin-angiotensin system.

DOI: 10.22456/1679-9216.99574

Received: 6 January 2020

Accepted: 10 April 2020

Published: 2 May 2020

School of Veterinary Medicine, Ceará State University (UECE), Fortaleza, CE, Brazil. CORRESPONDENCE: D. Rondina [davide.rondina@uece.br]. Av. Paranajana n. 1700. Campus do Itaperi. CEP 60714-903 Fortaleza, CE, Brazil.

INTRODUCTION

The role of renin-angiotensin system (RAS) in homeostatic balance and blood pressure regulation is well established [27], however, despite the confirmed presence of the main components of this system in reproductive tissues, the effects of these components on reproductive activity are not yet fully known [34]. Studies have reported correlations between the RAS and specific reproductive activities, such as the correlation of renin activity and use of ACE inhibitors with hormone concentration [6] and follicular development [33].

Currently, special attention has been given to Angiotensin-(1-7) (Ang-1-7) peptide. Ang-1-7 is generated from Angiotensin I or II by endopeptidases [14] and, although its production may be independent of ACE, it is known that the use of an ACE inhibitor would prevent the conversion of Angiotensin I into Angiotensin II, increasing the production of Ang-1-7 [5]. Higher levels of this peptide have been found in the follicular phases of rats [7]. Moreover, a greater presence of Angiotensin II has been observed in atrophic [8] and dominant follicles [13], showing that Angiotensin II and Ang-1-7 play a fundamental role in follicular development and atresia.

Despite the known effects on blood pressure and vasodilator activity, no study has investigated the effects of the use of an ACE inhibitor on ovarian blood perfusion in ruminants, as well as its association with the follicular development of hormonally stimulated animals. Therefore, this study aimed to determine the effect of the administration of enalapril maleate, an ACE inhibitor, on the ovarian and intraovarian blood flow and follicular development in goats during repeated hormonal stimulations.

MATERIALS AND METHODS

*Animals and experimental design*

The present study represents an effort to investigate how vasodilator action of ACE inhibitor affects the ovarian and intraovarian blood flow system and follicular dynamic following a primary evaluation focused on embryo production and oocyte quality [4].

Twenty Anglo-Nubian adult cross-bred goats were allocated according to the order of parity (Nulliparous n = 10; Multiparous n = 10) in two treatments (n = 5 of each treatment): Saline and Enal-ACE. All animals received a similar feeding and housing management with elephant grass chopped and concentrate to satisfy the nutrient requirement of breeding for non-dairy goats [23] and were kept in collective stalls, divided according to the order of parity, with free access to mineral supplement and water.

The animals selected to Enal-ACE group received Enalapril-maleate (Enalapril®)<sup>1</sup> crescent doses for three days (0.2 mg.kg<sup>-1</sup> BW and 0.3 mg.kg<sup>-1</sup> BW) of Enalapril-maleate for a total period of 6 days until reaching the dose stage at the beginning of estrus synchronization treatment of 0.4 mg.kg<sup>-1</sup> BW [12], which was maintained for 11 days (Figure 1). The injectable solution of Enalapril-maleate was obtained from tablets that were processed in a crucible and, after maceration, diluted and homogenized in 3 ml of 9% saline solution in a vortex for 2 min. Saline treatment animals received the same volume of saline solution at 9% as placebo. Enalapril-maleate and placebo were administered subcutaneously daily, at 7 am.

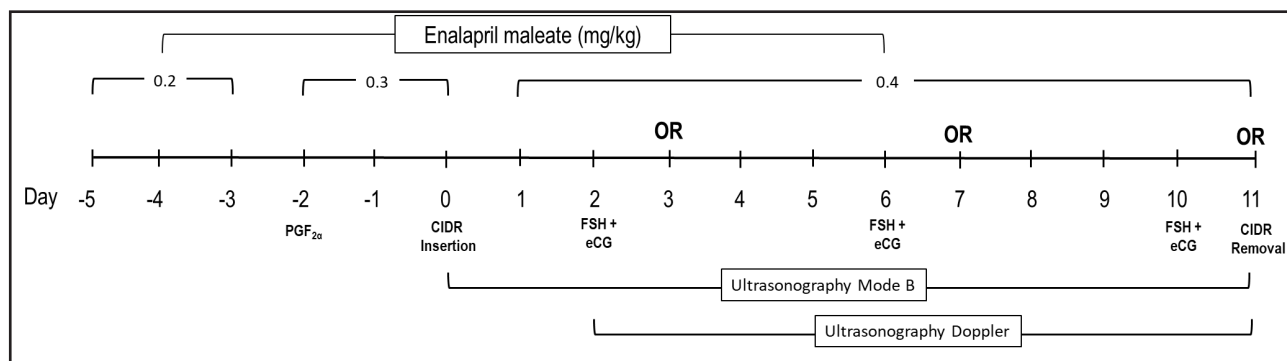


Figure 1. Timeline of Enalapril-maleate administration, ultrasound assessment, hormones treatment and serial oocyte retrieval (OR).

### *Estrous synchronization and hormonal stimulation*

Estrus synchronization and ovarian stimulation were performed according to Gibbons *et al.* [15]. In all goats was administrated *i.m.* 1-mL (0.075mg) of a PGF2 $\alpha$  analogue (Prolise<sup>®</sup>)<sup>2</sup> and inserted an intravaginal progesterone (CIDR<sup>®</sup>)<sup>3</sup> 48 h later. The intravaginal insert were removed after the last oocyte recovery. The follicular development was stimulated by the *i.m.* administration, at the same time, of a single dose of 60 mg of FSH (Folltropin<sup>®</sup>)<sup>4</sup> plus a single dose of eCG (300 UI, Novormon 5000<sup>®</sup>)<sup>5</sup>. The first FSH/eCG doses were administered 48 h after the dispositive insertion, being repeated every 4 days to complete three treatments (Figure 1). Oocytes retrieval was performed by laparoscopic ovum pick-ups 24 h after each FSH/eCG in order to induce regression of the stimulated follicular wave.

### *Ultrasound examinations*

Transrectal ultrasonography was performed daily on all 11 days of the hormonal treatment (Figure 1). Evaluations were carried out by using the color Doppler and B-mode real-time ultrasound scanner (model Z5 VET)<sup>6</sup> equipped with a linear transrectal transducer of 7.5 MHz. Goats were restrained in a standing position and the abdominal wall was compressed to facilitate the visualization of the uterus and ovaries. The rectum was lubricated using hydrosoluble contact gel prior to insertion of the transducer; the probe was positioned perpendicularly to the abdominal wall and the bladder was identified to orientate the visualization of the uterine horns. The probe was then rotated laterally to both sides to obtain the images of the ovaries artery, ovaries and ovarian antral follicles.

### *Ovaries and follicles*

B-mode ultrasonography was performed each 24 h (each 12 h on the days of FSH/eCG administration); and used to measure all ovarian antral follicles. For measurement of structures of interest, including the growth pattern of the ovarian follicles, ultrasonographic examinations were recorded as videos, followed by the capture and measurement of images (with several different projections of ovary) using the Image J<sup>®</sup> software<sup>7</sup>, which was previously calibrated. The mean diameter (average of two dimensions, vertical and horizontal) of each identified follicle was taken from images. The follicles present in both ovaries of each female were categorized according to their di-

ameter in small (< 3 mm), medium ( $\geq 3 < 5$  mm) and large follicles ( $\geq 5$  mm) [16].

### *Intraovarian blood flow and Doppler velocimetric parameters of ovarian artery*

Each day of FSH/eCG administration and 24 h later, the color Doppler was used to determine intraovarian blood flow and Doppler velocimetric parameters of ovarian artery. The settings of the scanner (Doppler sampling frequency (PRF) = 1.7 kHz and color gain = 70% or just below the background noise level recorded in a motionless animal) remained constant for the duration of the study. Both arbitrary-scale [Absence (AB); Low (LO) and Moderate-high (MH) (Figure 2) and quantitative analysis of the blood flow area (ImageJ<sup>®</sup>)<sup>7</sup> were used to assess the intraovarian blood flow in Doppler images, as described by Oliveira *et al.* [24], with modifications. Briefly, in the images containing the cross-sectional area of the ovary with the strongest color Doppler signal, the ovary was out-lined manually and the total ovarian area (TA) recorded. Subsequently, the color Doppler area (DA), representing follicular blood flow was computed for each ovary. Finally, a Doppler Area percentage (DA/TA  $\times$  100%) was obtained for each day and for each goat.

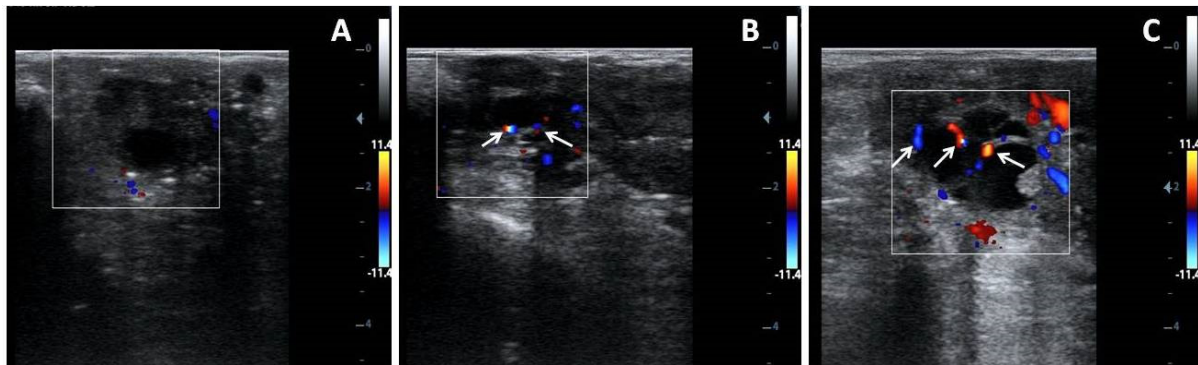
To evaluate the Doppler velocimetric parameters of the ovarian arteries, the left and right ovarian arteries were localized immediately after the intraovarian blood flow ultrasound evaluation. Blood flow was determined at the most prominent color spot in the ovarian pedicle within 5 mm of the ovary base. The ovarian artery could be identified as a single vessel winding around the ovarian vein. Thus, at this location the ovarian artery blood flow waveforms were obtained by activating the pulsed Doppler function and placing the Doppler gate with a diameter of 2 mm over the colored ovarian artery. The values of resistance index, end diastolic velocity and peak systolic velocity were calculated by the spectral Doppler waveform and estimated by the mean value of the measurements from both ovaries. The angle of insonation between the Doppler ultrasound beam and flow direction in the ovarian artery was 60° [30].

### *Statistical analysis*

Data were subjected to analysis of variance (ANOVA) using the GLM procedures (Statistica<sup>®</sup>)<sup>8</sup>. For Doppler velocimetrics parameters the model included the main factors treatment (Saline, Enal-

ACE), parity (Nulliparous and Multiparous), number of sessions of serial hormonal stimulation (Session 1, 2 and 3) and interaction treatment vs. parity, treatment vs. number of session. For data of follicles dynamics the main effect of time (Hours from oocyte retrieval), considering as interval of assessments used

for evaluating of ultrasonography type B, was added in the model and interaction treatment vs. time was also tested. Pairwise comparisons were performed by Newman-Keuls test. Frequency numbers from the arbitrary scores of Doppler blood evaluation were compared by qui square test.



**Figure 2.** Color Doppler ultrasonograms of goat's ovaries obtained after hormonal stimulation protocol and classified according to blood flow area in the follicular walls: Absence (A), Low (B) and Moderate-high (C) blood flow. White arrows indicate blood flow areas on the wall of antral follicles.

## RESULTS

### *Doppler velocimetry parameters of the ovarian artery*

Figure 2 illustrates the results of the Doppler parameters of ovarian arteries during the three sessions of hormonal stimulation. There was a 29% reduction in the systolic peak (Figure 3 A) between the first and last sessions in the group of animals treated with enalapril maleate. In the third hormonal stimulation, the average values of the systolic (Figure 3 A) and diastolic (Figure 3 B) peaks in the goats of the Enal-ACE group were significantly lower compared to those of the animals treated with saline solution. Ovarian artery resistance index values (Figure 4) of both groups had similar values throughout the hormone protocol.

### *Intraovarian blood flow*

Color Doppler flow imaging of intraovarian perfusion (Figure 5) showed no differences for both treatments in hormone protocol sessions 1 and 2. In the third session, only the groups not treated with enalapril maleate had a significant increase in the Doppler area. For this reason, in the last hormonal treatment (Session 3), the difference between the areas of the Enal-ACE group and the areas of the Saline group was - 39% for nulliparous animals and - 53% for multiparous animals (Figure 5).

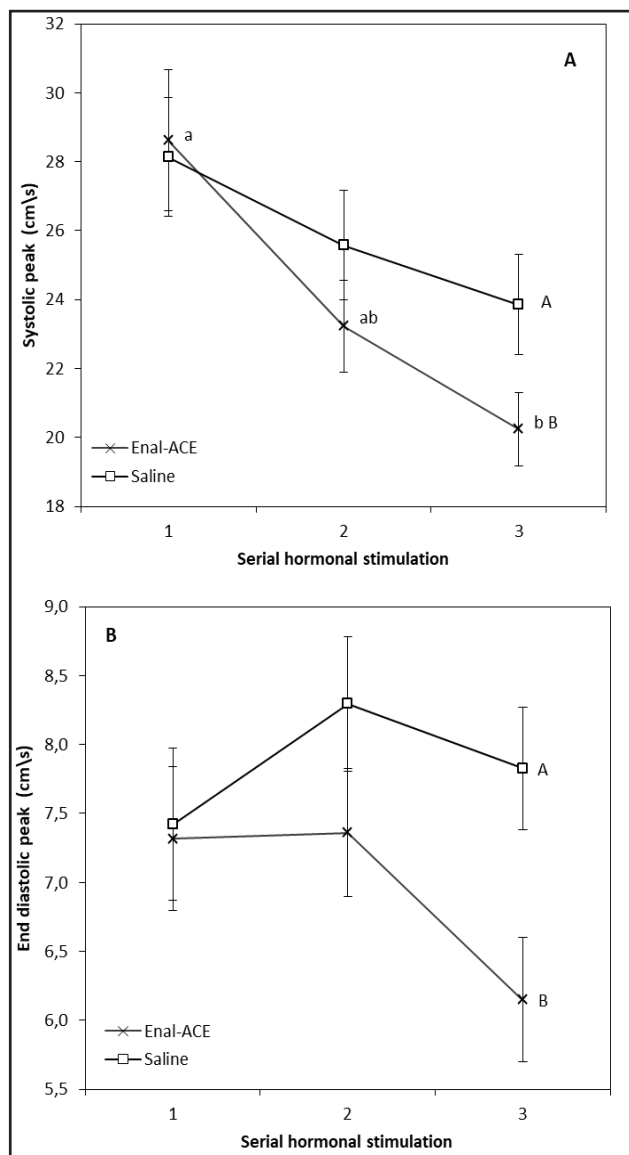
The intraovarian Doppler signal was also measured by assigning arbitrary scores (Table 1). In the first and second hormonal treatment, a high incidence of absent or low signal was observed. In the third session, in turn, more than 60% of the ovaries analyzed in the saline group had moderate-high Doppler signal (Table 1), this value being 1.7 times higher than that observed in the ovaries of the group treated with enalapril maleate (36.8%).

### *Follicular dynamics*

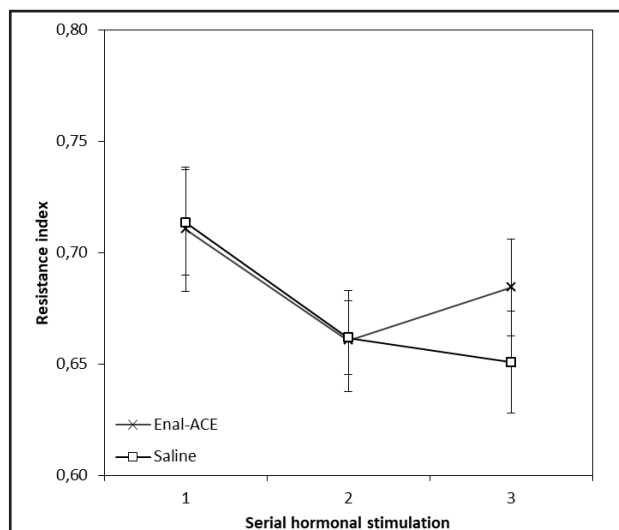
The animals treated with enalapril maleate had a follicular population with lower mean diameter ( $P < 0.001$ ) than the Saline groups (Table 2). Figure 6 shows the average values of the maximum follicular size for each hormonal session. Throughout the hormone protocol, the animals of the Enal-ACE group were smaller ( $P < 0.001$ ) than those of the Saline group.

With regard to the follicular population (Table 2), the Enal-ACE group had a higher proportion of small follicles ( $< 3$  mm) and a lower proportion of large follicles ( $\geq 5$  mm). Significant interactions (Table 2) between the treatment and the oocyte recovery time ( $P = 0.01$ ), the hormonal session ( $P = 0.02$ ), and the parity group ( $P < 0.001$ ) were observed in large follicles. These interactions were described separately in figures 7, 8, and 9, respectively.

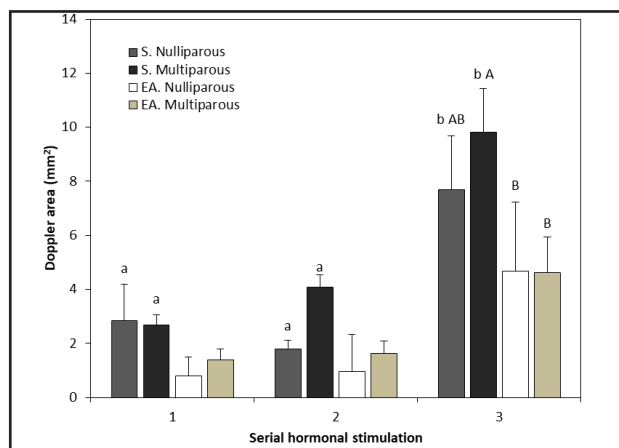




**Figure 3.** Systolic peak (A) and diastolic peak (B) of ovary artery recorded by doppler ultrasound evaluation during serial hormonal stimulation (Session 1, 2 and 3) from saline and enalapril-maleate treated goats. <sup>a,b</sup>Bars with different letters between serial hormonal stimulation differ ( $P < 0.05$ ). <sup>A,B</sup>Bars with different letters between Group differ ( $P < 0.05$ ). Values are expressed as mean  $\pm$  standard error of the mean.



**Figure 4.** Resistance index of ovary artery from Doppler ultrasound evaluation recorded during serial hormonal stimulation (Session 1, 2 and 3) from saline and enalapril-maleate treated goats. <sup>a,b</sup>Bars with different letters between serial hormonal stimulation differ ( $P < 0.05$ ). <sup>A,B</sup>Bars with different letters between Group differ ( $P < 0.05$ ). Values are expressed as mean  $\pm$  standard error of the mean.



**Figure 5.** Ovarian color doppler intraovarian area recorded during serial hormonal stimulation (Session 1, 2 and 3) from saline and enalapril-maleate treated goats with different parity (Nulliparous and Multiparous). <sup>a,b</sup>Bars with different letters between serial hormonal stimulation differ ( $P < 0.05$ ). <sup>A,B</sup>Bars with different letters between Group differ ( $P < 0.05$ ). Values are expressed as mean  $\pm$  standard error of the mean.

**Table 1.** Arbitrary blood flow scores (AB, LO, MH) based on color Doppler intraovarian evaluation recorded during each session of serial hormonal stimulation (1, 2 and 3) from goats with different parity and treated with enalapril-maleate.

Treatment	Parity	Session 1				Session 2				Session 3			
		AB %	LO %	MH %	N	AB %	LO %	MH %	N	AB %	LO %	MH %	N
Saline	Nulliparous	38.9 ABa	50.0 A	11.1 Bb	18	18.8 ab	62.5	18.8 ab	16	6.3 Bb	31.3 AB	62.5 Aa	16
	Multiparous	26.7	53.3	20.0	15	13.3 B	60.0 A	26.7 AB	15	8.3 B	25.0 AB	66.7 A	12
Enal-ACE	Nulliparous	61.1 A	33.3 AB	5.6 Bb	18	60.0 A	33.3 AB	6.7 Bb	15	36.8	26.3	36.8 a	18
	Multiparous	47.1	35.3	17.6 ab	17	38.9 A	55.6 A	5.6 Bb	18	15.8	47.4	36.8 a	19

Values as expressed as percentage (%) of ovaries that exhibit the arbitrary score. AB= Absence of signal color doppler; LO = Low signal of color doppler; MH = Moderate-high signal of color doppler; <sup>a,b</sup> $P < 0.05$  differences between sessions in the same score; <sup>A,B</sup> $P < 0.05$ , differences between scores in the same session. N= number of ovaries evaluated.

**Table 2.** Follicular dynamics from goats with different parity and treated with enalapril-maleate.

Parameter	N	Treatment		Treatment	Parity	P-value				
		Saline	Enal-ACE			SHS	Time	TR x P	TR x SHS	TR x T
Follicles < 3 mm, n	490	0.8 ± 0.1	1.3 ± 0.1	<0.001	0.03	<0.001	0.98	0.70	0.97	0.29
Follicles ≥ 3 < 5 mm, n	787	1.8 ± 0.1	1.7 ± 0.1	0.23	0.22	<0.001	0.58	0.80	0.85	0.58
Follicles ≥ 5 mm, n	387	1.1 ± 0.1	0.6 ± 0.05	<0.001	<0.01	<0.001	0.02	<0.001	0.02	0.01
Mean follicle size, mm	1664	4.5 ± 0.1	3.9 ± 0.1	<0.001	<0.001	<0.001	<0.01	0.07	0.47	0.49

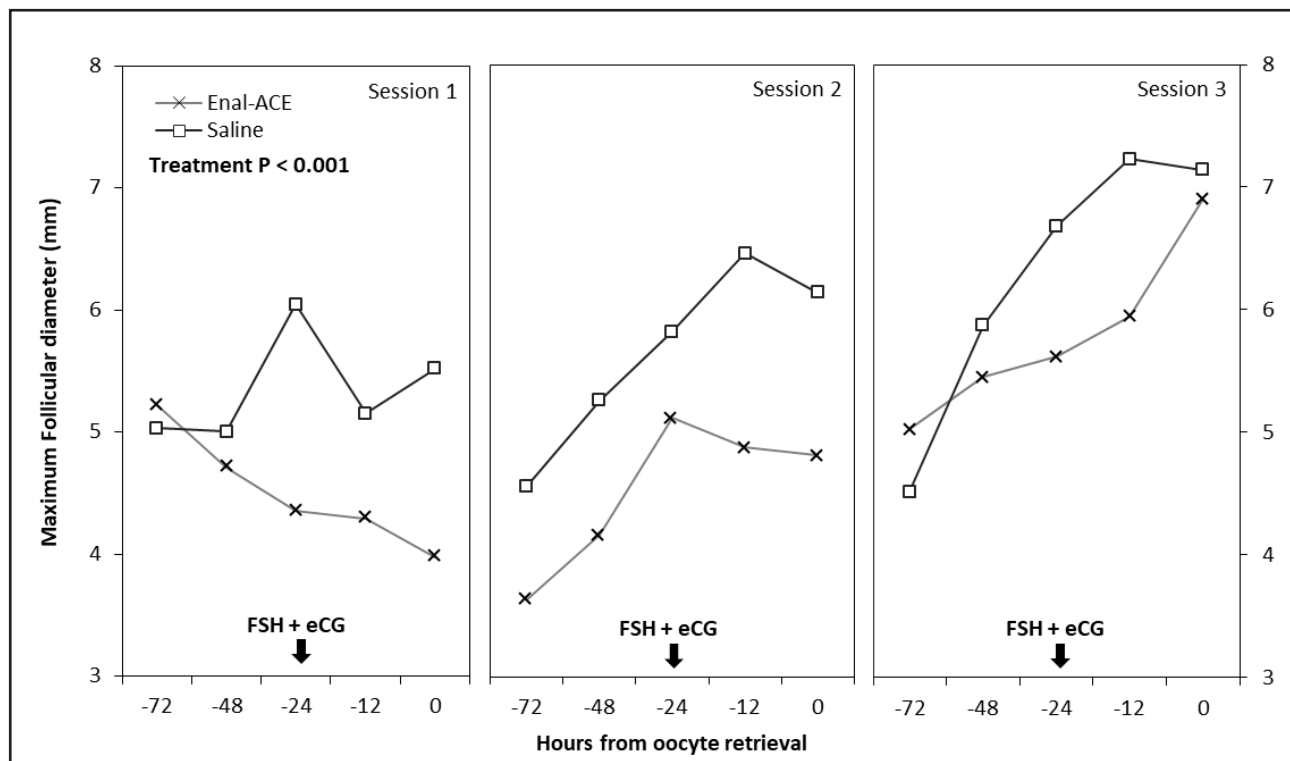
Values are expressed as mean ± standard error of the mean. TR= treatment; P = parity; SHS = sessions of serial hormonal stimulation; Time = hours from oocyte retrieval.

In the animals of the group treated with saline solution the proportion of large follicles (≥ 5 mm) started to significantly increase 24 h before oocyte recovery (Figure 6) concomitantly to gonadotropin administration. The animals of the Enal-ACE group had statistically similar values throughout the analyzed time interval (Figure 7).

With regard to hormonal treatments (Figure 8), the number of large follicles in the Saline group increased from the second session and in the animals treated with enalapril maleate it increased from the

third session. In the second and third hormonal sessions, the number of follicular structures was lower ( $P < 0.05$ ) in the Enal-ACE group than in the Saline group (Figure 8).

The nulliparous females of the Enal-ACE group had a lower proportion of large follicles (Figure 9) compared to the saline group, otherwise, there were no differences between the treatments in multiparous goats. In the group treated with enalapril maleate, higher number of large follicles was observed in multiparous animals than in the nulliparous ones (Figure 9).



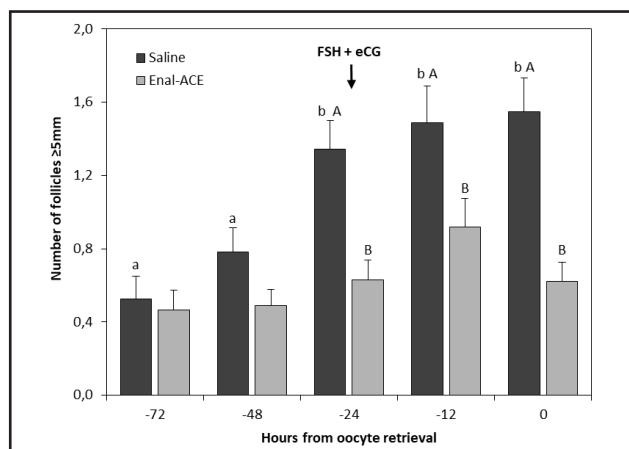
**Figure 6.** Maximum follicular size dynamics recorded during the serial hormonal stimulation (session 1,2 and 3) in goats from saline group (white mark and full line) or treated with enalapril-maleate (asterisk mark and grey line). Analysis of variance results for the treatment effect is represented in the figure. Values are shown as the mean of maximum follicles size measured by ultrasonography (n = 453, SEM = 0.08).

DISCUSSION

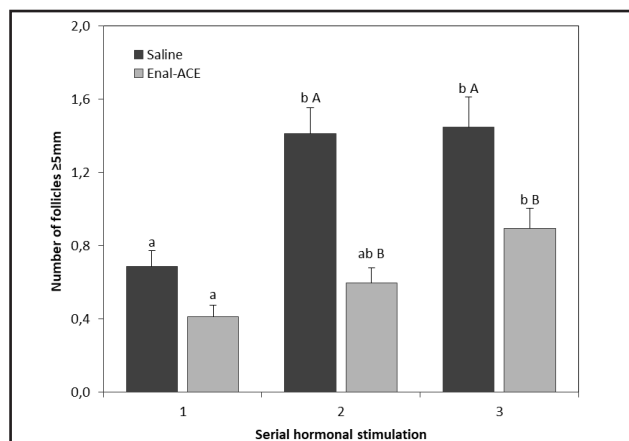
Several studies have shown that, beside to affecting blood pressure, the renin-angiotensin system (RAS) acts in several other organs, such as the uterus and ovaries, thus affecting important reproductive processes, such as steroidogenesis, folliculogenesis, ovulation, and pregnancy [11]. Our results confirmed the hypotensive effect of enalapril maleate on the ovarian artery and intraovarian blood flow, also showing that the administration of the drug reduced the process of follicular depletion and the growth of large follicles. The change in follicular dynamics became even more evident after the administration of gonadotropins, when it was not possible to observe a synergistic effect between follicular development and hormonal treatment.

The variability of the ovarian response to hormonal stimulation treatments in goats, such as the number of recruited follicles and oocytes collected, is considered one of the main limiting factors to achieve satisfactory results in the production of in vitro embryos in this specie. It is known that this variability depends of several factors, such as breed, age, and nutritional status of the animal [26], as well as the hormone protocol used, which vary according to the dosage and type of gonadotropin used, and the interval between administrations [28]. Thus, the control of intrinsic and extrinsic factors that affect the ovarian response has been investigated by several researchers in order to improve the efficiency of reproductive biotechnologies. In general, recent studies have recommended the use of short-term hormonal treatments and low dosage, aiming not only at improving the handling, but also at reducing the cost. Moreover, it has been demonstrated that the use of ‘one-shot’ treatments with follicle stimulating hormone (FSH) associated with equine chorionic gonadotropin (eCG) [15] provides satisfactory results when compared to traditional multiple-dose FSH treatments [1], thus reducing the possibility of formation of anti-FSH antibodies and the consequent decrease in ovarian response [31].

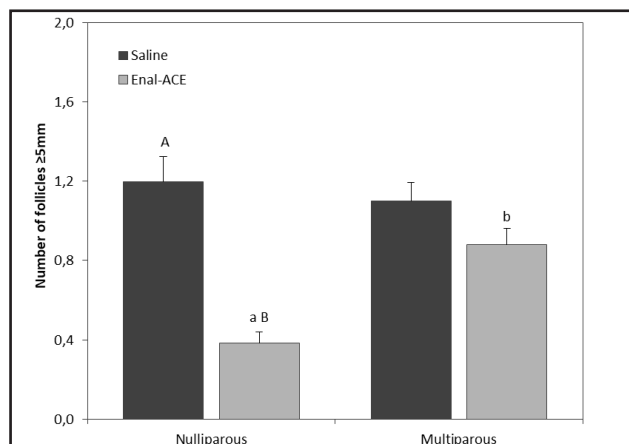
The presence and participation of various components of the renin-angiotensin system in the reproductive tract of domestic animals is known. The exogenous manipulation of this system has been manipulated in several ways, among them the use of ACE inhibitors aiming at improving reproductive biotechnologies in small ruminants, such as the response to estrus synchronization and superovulation and fixed-time artificial insemination



**Figure 7.** Effect of interaction Treatment vs. Time (hours from oocyte retrieval) on number of follicles with size ≥ 5 mm from saline and enalapril-maleate treated goats. <sup>a,b</sup>Bars with different letters between times differ ( $P < 0.05$ ). <sup>A,B</sup>Bars with different letters between Group differ ( $P < 0.05$ ). Values are expressed as mean ± standard error of the mean.



**Figure 8.** Effect of interaction Treatment vs. serial hormonal stimulation (Session 1,2 and 3) on number of follicles with size ≥ 5 mm from saline and enalapril-maleate treated goats. <sup>a,b</sup>Bars with different letters between serial hormonal stimulation differ ( $P < 0.05$ ). <sup>A,B</sup>Bars with different letters between Group differ ( $P < 0.05$ ). Values are expressed as mean ± standard error of the mean.



**Figure 9.** Effect of interaction Treatment vs. parity (nulliparous and multiparous) on number of follicles with size ≥ 5 mm from saline and enalapril-maleate treated goats. <sup>a,b</sup>Bars with different letters between parity differ ( $P < 0.05$ ). <sup>A,B</sup>Bars with different letters between Group differ ( $P < 0.05$ ). Values are expressed as mean ± standard error of the mean.

(FTAI) [7,12]. In this context, the main research focus has been on the possible positive effects of Angiotensin-(1-7) peptide, which has its levels increased by the blocking of the conversion of Angiotensin I to Angiotensin II by an ACE inhibitor in important reproductive processes, such as steroidogenesis, folliculogenesis, and ovulation, since its levels are increased during the follicular phases (proestrus and estrus). Moreover, it has been demonstrated that the infusion of Angiotensin-(1-7) in rat ovaries increased the production of estradiol and progesterone, and the ovulation rate [33]. Similarly, a higher concentration of estradiol was observed in sheep subcutaneously injected with enalapril [7].

The vasodilator effects of ACE inhibitors are already well known. In sum, ACE promotes the synthesis of the Angiotensin II vasoconstrictor and increases the production of bradykinin, which increases the contractility of smooth muscle [21]. Despite this knowledge, no study had investigated the correlation between ACE inhibitors and ovarian blood flow in goats, nor their effect on follicular dynamics. In this context, B-mode and color and spectral Doppler examinations of arteries and tissues that compose the reproductive tract have been performed in order to investigate the effect of ACE inhibitors on the reproductive function of the female in many ways, from variations during pregnancy and different stages of the estrous cycle to responses to hormonal treatments and correlations with oocyte quality [9,16,30].

It is known that blood flow at the uterine and ovarian levels, measured from parameters of vascular pressure or doppler area, and the follicular pattern in the ovaries, undergo severe changes according to the estrous cycle phase in some species (mares [3]; ewes [10]; cow [17]). Moreover, studies report that a good blood perfusion of the ovarian artery [9] and follicular wall [16] is essential for the development of follicles and the production of high-quality oocytes. Oocytes included in follicles with low blood supply are likely to be exposed to fewer growth factors, gonadotropins, steroid precursors, among other nutrients considered essential for follicular development, ovulation, and oocyte maturation [25].

In the present study, the protocol for enalapril proved to be efficient in the progressive reduction of the systolic peak of the ovarian artery during the hormonal stimulation sessions but did not alter vascular resistance. The cumulative effect of the drug was clearly

observed during the evaluation of intraovarian blood flow, especially when there was a marked decrease in the area and Doppler signal of the follicular walls in the third session. The pharmacokinetics of enalapril elimination can last up to 35 h, being able to maintain residual amount after treatments with 24 h interval between doses [32]. It is worth noting that although another ACE inhibitor, captopril, has already been tested on mares [3] and rabbits [2], it provides contradictory results, with increased or decreased uterine and ovarian blood flow being reported.

Studies on the changes in blood supply at the ovarian level due only to stimulatory hormonal treatments are still scarce and controversial. In a recent study, Souza *et al.* [30] compared the velocimetric Doppler parameters of the ovarian artery in goats and did not observe changes in the vascular system after a one-shot administration of 300 IU of eCG and 70 mg of porcine FSH. Honnens *et al.* [17] also found no relationship between follicular response and velocimetric Doppler parameters of the ovarian artery in a stimulatory hormonal treatment with eCG in cows.

According to Matsui and Myiamoto [19], the antral follicular development occurs concomitantly to and depends on the increase of blood flow in the tissue layer, which comprises the outer wall of the ovarian follicles. Moreover, the increase and intensity of this blood flow are closely related to the ovulatory process [18]. Taken together, these results suggest that the hypotensive effects observed in our experiment result from the treatment with the ACE inhibitor and that this alteration in hemodynamic parameters is the main responsible for the lower follicular response observed in animals treated with the drug because the females in the Enal-ACE group had a pattern of lower follicular development, mainly due to the scarce presence and diameter of large follicles.

The results on follicular dynamics supports the main hypotheses to date regarding the effects of enalapril on folliculogenesis, that they enhance follicular progress since higher ovulation rates in rats [33] and pregnancy and prolificity in goats [12] were reported in females treated with enalapril. Moreover, an increase in estradiol concentrations in animals treated with an ACE inhibitor [7,33] has been commonly reported by the experiments, which could be due to the higher number or larger diameter of follicles, which was not found under our experimental conditions.



Although the mechanism in which Angiotensin (1-7) influences estradiol production is not yet well understood, it is known that Angiotensin (1-7) activates phosphoinositide 3-kinase protein kinase B (PI3K/Akt) through the Mas receptor [29]. According to McDonald et al. [20], the activation of this pathway is necessary for the stimulatory actions of FSH on aromatase expression and on estradiol secretion. Although several studies point to positive effects of Angiotensin (1-7) on the final processes of follicular development and ovulation, it is necessary to understand the effect of different hormonal protocols on the activity and concentration of Angiotensin (1-7) during all phases of the estrous cycle. Some studies have reported a greater expression of Angiotensin (1-7) during the follicular phase. In our study, for example, the progestin implant, necessary to maintain control of follicular development, remained in the female throughout the treatment with Enalapril, including during ultrasonographic measurements. Therefore, further studies are necessary to elucidate possible effects of the administration of an ACE inhibitor on ovarian activity, especially in the expression of genes associated with follicular, oocyte and embryonic development.

#### CONCLUSION

The administration of enalapril maleate during 11 days of hormone treatment induced a progressive reduction in the hemodynamic parameters of the ovarian artery as well as in intraovarian perfusion. Concomitantly, there was a decrease in follicular depletion and

in the proportion of large follicles, moreover a smaller follicular diameter was observed in the animals that received the drug. The change in follicular dynamics was most evident from the follicular stimulation hormonal treatment. Based on these results, we can conclude that the use of enalapril maleate as an inhibitor of the renin-angiotensin system in goats under the present experimental conditions did not provide evident advantages in reproductive terms.

#### MANUFACTURERS

<sup>1</sup>Laboratório Teuto Brasileiro. Anápolis, GO, Brazil.

<sup>2</sup>ARSA S.R.L. Buenos Aires, Argentina.

<sup>3</sup>InterAg. Hamilton, New Zealand.

<sup>4</sup>Vetrepharm Inc. London, Canada.

<sup>5</sup>Syntex, Buenos Aires, Argentina.

<sup>6</sup>Mindray Bio-medical Electronics Co. Ltd. Nanshan, Shenzhen, China.

<sup>7</sup>National Institutes of Health, Millersville, USA

<sup>8</sup>TIBCO Software. Palo Alto, CA, USA.

**Funding.** This work was supported by grant Proex grant No. 23038.002808/2017-56 funded by Capes/Brazil. Moreno M.E. was the recipient of a scholarship from CNPq/Brazil. Rondina D. is senior investigator of CNPq/Brazil.

**Ethical approval.** All procedures performed in studies involving animals were in accordance with the ethical standards of the institution or practice at which the studies were conducted (Ethics Committee in Animal Experimentation of the Ceará State University, N. 01937655/2019).

**Declaration of interest.** The authors report no conflicts of interest. The authors alone are responsible for the content and writing of the paper.

#### REFERENCES

- 1 Baldassarre H., Wang B., Kafidi N., Keefer C., Lazaris A. & Karatzas C.N. 2002.** Advances in the production and propagation of transgenic goats using laparoscopic ovum pick-up and *in vitro* embryo production technologies. *Theriogenology*. 57: 275-284.
- 2 Binder N.D. & Faber J.J. 1992.** Effects of captopril on blood pressure, placental blood flow and uterine oxygen consumption in pregnant rabbits. *The Journal Pharmacology and Experimental Therapeutics*. 260: 294-299.
- 3 Bollwein H., Weber F., Steffen S. & Stolla R. 2004.** The effect of acetylsalicylic acid and captopril on uterine and ovarian blood flow during the estrous cycle in mares. *Theriogenology*. 61: 301-309.
- 4 Bravo P.A., Moreno M.E., Fernandes C.C.L., Rossetto R., Cavalcanti C.M., Fernandes D.P. & Rondina D. 2019.** Effect of continuous administration of enalapril maleate on the oocyte quality and *in vitro* production of parthenote embryos in nulliparous and multiparous goats undergoing serial laparoscopic ovum pick-up. *Animals*. 9: 868.
- 5 Brosnihan K.B., Neves L.A.A., Anton L., Joyner J., Valdes G. & Merrill D.C. 2004.** Enhanced expression of Angiotensin (1-7) during pregnancy. *Brazilian Journal of Medical and Biological Research*. 37: 1255-1262.
- 6 Costa A.P., Fagundes-Moura C.R., Pereira V.M., Silva L.F., Vieira M.A., Santos R.A. & Reis A.M. 2003.** Angiotensin-(1-7): a novel peptide in the ovary. *Endocrinology*. 144: 1942-1948.
- 7 Costa A.S., Junior A.S., Viana G.E.N., Matorini M.C.S., Reis A.M. & Costa A.P.R. 2014.** Inhibition of Angiotensin-Converting Enzyme increases oestradiol production in ewes submitted to oestrus synchronization protocol. *Reproduction in Domestic Animals*. 49: 53-55.

- 8 Daud A.I., Bumpus F.M. & Husain A. 1988. Evidence for selective expression of angiotensin II receptors on atretic follicles in the rat ovary: an autoradiographic study. *Endocrinology*. 122: 2727-34.
- 9 Du B., Takahashi K., Ishida G.M., Nakahara K., Saito H. & Kurachi H. 2006. Usefulness of intraovarian artery pulsatility and resistance indices measurements on the day of follicle aspiration for the assessment of the oocyte quality. *Fertility and Sterility*. 85: 366-370.
- 10 El-sherry T.M., Derar R. & Bakry R. 2013. Changes in blood flow in ovine follicles and serum concentration of estradiol 17 beta (E2) and nitric oxide (NO) around the time of ovulation in Ossimi ewes. *Animal Reproduction Science*. 138: 188-193.
- 11 Feitosa L.C.S., Viana G.E.N., Reis A.M. & Costa A.P.R. 2010. Sistema Renina Angiotensina Ovariano. *Revista Brasileira de Reprodução Animal*. 34: 243-251.
- 12 Fernandes Neto V.P., Silva M.N.N. & Costa A.S. 2018. ACE inhibition in goats under fixed-time artificial insemination protocol increases the pregnancy rate and twin births. *Reproduction in Domestic Animals*. 53: 1006-1008.
- 13 Ferreira R., Gasperin B., Santos J., Rovani M., Santos R.A., Gutierrez K., Oliveira J.F., Reis A.M. & Gonçalves P.B. 2011. Angiotensin II profile and mRNA encoding RAS proteins during bovine follicular wave. *Journal of the Renin Angiotensin-Aldosterone System*. 12: 475-482.
- 14 Forster C. & Le Tran Y. 1997. Angiotensin-(1-7) and the rat aorta: modulation by the endothelium. *Journal of Cardiovascular Pharmacology*. 30: 676-682.
- 15 Gibbons A., Pereyra Bonnet F., Cueto M., Catala M., Salamone D. & González-Bulnes A. 2007. Procedure for maximizing oocyte harvest for *in vitro* embryo production in small ruminants. *Reproduction in Domestic Animals*. 42: 423-426.
- 16 Ginther O.J., Gastal E.L., Gastal M.O., Siddiqui M.A. & Beg M.A. 2007. Relationships of follicle versus oocyte maturity to ultrasound morphology, blood flow, and hormone concentrations of the pre-ovulatory follicle in mares. *Biology of Reproduction*. 77: 202-208.
- 17 Honnens A., Niemann H., Herzog K., Paul V., Meyer H.H.D. & Bollwein H. 2009. Relationships between ovarian blood flow and ovarian response to eCG-treatment of dairy cows. *Animal Reproduction Science*. 113: 1-10.
- 18 Lass A. & Brinsden P. 1999. The role of ovarian volume in reproductive medicine. *Human Reproduction Update*. 3: 256-266.
- 19 Matsui M. & Miyamoto A. 2009. Evaluation of ovarian blood flow by colour Doppler ultrasound: practical use for reproductive management in the cow. *Veterinary Journal*. 181: 232-240.
- 20 McDonald C.A., Millena A.C., Reddy S., Finlay S., Vizcarra J., Khan S.A. & Davis J.S. 2006. Follicle-stimulating hormone-induced aromatase in immature rat Sertoli Cells requires an active Phosphatidylinositol 3-Kinase pathway and is inhibited via the Mitogen-Activated Protein Kinase signaling pathway. *Molecular Endocrinology*. 20: 608-618.
- 21 Murone C., Chai S.Y., Mueller Esterl W., Mendelsohn F.A. & Clements J. 1999. Localization of bradikinin B2 receptors in the endometrium of rat uterus and effects of estrogen and progesterone. *Endocrinology*. 140: 3372-3382.
- 22 Nielsen A.H., Schauer K.H., Svenstrup B. & Poulsen K. 2002. Angiotensin Converting Enzyme in Bovine Ovarian Follicular Fluid and its Relationship with Oestradiol and Progesterone. *Reproduction in Domestic Animals*. 37: 81-85.
- 23 NRC - National Research Council. 2007. *Nutrient requirements of small ruminants: Sheep, goats, cervids, and new world camelids*. Washington, DC: The National Academies Press, 362p.
- 24 Oliveira M.E.F., Feliciano M.A.R., D'Amato C.C., Oliveira L.G., Bicudo S.D., Fonseca J.F., Vicente W.R.R., Visco E. & Bartlewski P.M. 2014. Correlations between ovarian follicular blood flow and superovulatory responses in ewes. *Animal Reproduction Science*. 144: 30-37.
- 25 Pancarci S.M., Güngör O., Atakisi O., Cigremis Y., Arı U.C. & Bollwein H. 2011. Changes in follicular blood flow and nitric oxide levels in follicular fluid during follicular deviation in cows. *Animal Reproduction Science*. 123: 149-156.
- 26 Paramio M.T. 2010. *In vivo* and *in vitro* embryo production in goats. *Small Ruminant Research*. 89: 144-148.
- 27 Peach M.J. 1977. Renin-angiotensin system: Biochemistry and mechanisms of action. *Physiological Reviews*. 57: 313-370.
- 28 Pierson J., Wang B., Neve N., Sneek L., Karatzas C.N. & Baldassarre H. 2004. Effects of repetition, interval between treatments and season on the results from laparoscopic ovum pick-up in goats. *Reproduction, Fertility and Development*. 16: 795-799.

- 29 **Sampaio W.O., Santos R.A., Faria-Silva R., Machado L.T., Schiffrin E.L. & Touyz R.M. 2007.** Angiotensin-(1-7) through receptor Mas mediates endothelial nitric oxide synthase activation via Akt-dependent pathways. *Hypertension*. 49: 185-192.
- 30 **Souza S.S., Alves B.G., Alves K.A., Santos J.D.R., Diogenes Y.P., Bhat M.H., Melo L.M., Freitas V.J.F. & Teixeira D.I.A. 2016.** Relationship of Doppler velocimetry parameters with antral follicular population and oocyte quality in Canindé goats. *Small Ruminant Research*. 141: 39-44.
- 31 **Remy B., Baril G., Vallet J.C., Dufour R., Chouvet C., Saumande J., Chupin D. & Beckers J.F. 1991.** Are antibodies responsible for a decreased superovulatory response in goats which have been treated repeatedly with porcine follicle stimulating hormone? *Theriogenology*. 36: 389-399.
- 32 **Ribeiro W. & Muscara M.N. 2001.** Características farmacocinéticas de antagonistas de cálcio, inibidores da ECA e antagonistas de angiotensina II em humanos. *Revista Brasileira de Hipertensão*. 8: 114-124.
- 33 **Viana G.E.N., Pereira V.M., Honorato-Sampaio K., Oliveira C.A., Santos R.A.S. & Reis A.M. 2011.** Angiotensin-(1-7) induces ovulation and steroidogenesis in perfused rabbit ovaries. *Experimental Physiology*. 96: 957-965.
- 34 **Yoshimura Y. 1997.** The ovarian renin-angiotensin system in reproductive physiology. *Frontiers in Neuroendocrinology*. 18: 247-291.