

Non-Cardiogenic Thromboembolism in a Persian Cat with Hypertrophic Cardiomyopathy

Nathália Lopes Fontoura Mateus^{1,2}, Paula Velozo Leal³, Beatriz Candolo Marques⁴, Karen Fernanda da Silva², Douglas Rodrigo Mattei² & Elizabeth Regina Carvalho⁵

ABSTRACT

Background: Hypertrophic cardiomyopathy is the most common acquired cardiovascular disease in the feline species. A frequent complication of this cardiomyopathy is the development of cardiac congestive failure, left atrial enlargement and subsequent development of arterial thromboembolism. In a significant percentage of affected animals there is progression to congestive heart failure, resulting in cyanosis and dyspnea, often the first clinical signs reported by owners. This is a report of a 10-year-old Persian cat with hypertrophic cardiomyopathy and venous and arterial thromboembolism of non-cardiogenic origin.

Case: The patient was referred for cardiac evaluation, arterial thromboembolism was the suspected cause of tetraparesis. On clinical examination, a metacarpal pulse was present in all limbs; there was no cyanosis or peripheral hypothermia thus, ruling out a thromboembolic event in the limbs. Changes consistent with feline asthma and pulmonary edema were seen on radiographs, therefore hypertrophic cardiomyopathy was suspected. Treatment with enalapril (0.25 mg/kg every 12 h) for the heart condition and prednisolone (1 mg/kg every 24 h) for asthma was started. Nine days later, the patient developed mixed dyspnea (inspiratory and expiratory) and was hospitalized with signs consistent with arterial thromboembolism: paralysis and cold extremities in the right and left pelvic limbs. The patient was euthanized due to the poor prognosis. *Postmortem* and histopathological findings revealed left ventricular concentric hypertrophy, with no valvular changes; disseminated intravascular coagulation, with thrombi in the arterial (iliac arteries, pancreatic and renal vessels) and venous (pulmonary and renal veins) beds; as well as multiple neoplastic lung masses, identified as scirrhous pulmonary adenocarcinoma, responsible for increased interstitial radiopacity. Metastasis was also identified at the tracheal bifurcation, causing radiographic changes similar to the alveolar pattern of pulmonary edema.

Discussion: The origin of the concentric left ventricular hypertrophy was not established. Both primary hypertrophy, due to breed-related genetic predisposition or secondary hypertrophy, due to systemic hypertension from chronic kidney disease are possibilities. However, despite the left ventricular concentric hypertrophy and the presence of thrombus under the mitral valve, it was not thought that the patient had cardiogenic thromboembolism, since this would not explain the venous thrombi. The arterial and venous thromboembolism in this case were the result of paraneoplastic syndrome due to pulmonary adenocarcinoma, which was a triggering factor for disseminated intravascular coagulation and multiple thrombus formation, both in arterial and venous beds. Tumor cells may promote direct and indirect modifications in the coagulation cascade and, thus hypercoagulability. The hypercoagulatory state promoted by the tumor associated with the Virchow triad seen in feline species, explains the occurrence of thrombosis in this case report. Sensitive imaging tests, such as computed tomography or magnetic resonance imaging, may be required in middle-aged cats with hypertrophic cardiomyopathy and clinical presentations of thromboembolism or respiratory signs, in order to exclude pulmonary neoplasm as a differential diagnosis for thrombus formation and dyspnea. Furthermore, it is speculated that the antitumor effect of heparin used in the treatment for arterial thromboembolism may delay the diagnosis of lung neoplasia in cats.

Keywords: arterial and venous thromboembolism, heparin, hypercoagulability, scirrhous pulmonary adenocarcinoma.

DOI: 10.22456/1679-9216.100519

Received: 25 September 2019

Accepted: 30 December 2019

Published: 31 January 2020

¹Setor de Clínica Médica de Pequenos Animais, Universidade da Grande Dourados (UNIGRAN), Dourados, MS, Brazil. ²Centro de Especialidades Médico Veterinário (CEMEV), Campo Grande, MS, Brazil. ³Departamento de Anatomia, Patologia e Clínicas, Universidade Federal da Bahia (UFBA), Salvador, BA, Brazil. ⁴Clínica Veterinária Mania de Gato, Campo Grande, MS, Brazil. ⁵Departamento de Medicina Veterinária, Universidade Federal do Espírito Santo, UFES, Alegre, ES, Brazil. CORRESPONDENCE: N.L.F. Mateus [nathaliafontouraveterinaria@gmail.com] & E.R. Carvalho [beth_rcarvalho@hotmail.com]. Clínica Veterinária UNIGRAN. Rua Passo Fundo n. 55. CEP 79823-211 Dourados, MS, Brazil.

INTRODUCTION

Arterial thromboembolism is usually characterized by the formation of a clot (thrombus) inside the left heart chambers and its subsequent dispersion to the arterial system. The obstruction of an artery by the thrombus results in clinical manifestations due to acute ischemia of the tissue supplied by the obstructed vessel [29].

Feline hypertrophic cardiomyopathy is considered the main cause of arterial thromboembolism in the species due to left atrial dilatation in advanced stages of the disease [29]. Hypertrophic cardiomyopathy accounts for 57.5% of the cardiomyopathies diagnosed in domestic cats [7], with a predisposition in middle-age males, and a genetic predisposition in Maine Coons, Ragdolls, and Persians. In these breeds, genetic mutations lead to functional alterations in sarcomeric proteins, promoting concentric hypertrophy, rigidity and decreased left ventricular distensibility [22,29].

Feline hypertrophic cardiomyopathy structural changes result in hemodynamic modifications, such as systolic and diastolic dysfunction and consequent reduction of cardiac output and activation of the compensatory mechanisms of congestive heart failure [1,9,25,32]. Atrial congestion and remodeling due to low left ventricular compliance, associated with Virchow triad factors (hypercoagulability, endothelial lesion, and blood stasis) result in an increased risk of hypertrophic cardiomyopathy-affected cats developing arterial thromboembolism [29].

This report describes the case of a Persian cat, diagnosed with hypertrophic cardiomyopathy with non-cardiogenic arterial and venous thromboembolism.

CASE

A 10-year-old male Persian cat, weighing 4.8 kg, was referred for cardiac evaluation due to suspected arterial thromboembolism. Owners reported lethargy, less interaction with the environment and people, sporadic cough and difficulty walking and swallowing. The patient had been previously treated for hemoparasitosis using doxycycline (10 mg/kg, once a day, orally). Vaccines were up to date (anti-rabies vaccine and tetravalent vaccine) and immunochromatographic tests for feline immunodeficiency and feline leukemia virus had been negative as a kitten.

During the cardiologic evaluation, the patient had no hind limb paralysis, however, motor incoordination due to tetraparesis was observed. No cold

extremities or cyanotic pads were detected. In addition, distal pulses were detected in all limbs using the portable vascular Doppler method (DV 610B)¹. Systolic blood pressure, measured by the same method, was 149 mmHg. The cat was alert, with normal colored ocular and oral mucosal membranes, but cyanotic penile mucosa; normal temperature and lymph node size; absence of ocular, nasal or penile secretions; absence of sensitivity during abdominal, epaxial and cervical palpation; heart rate of 204 beats per minute (bpm); standard heart sounds at auscultation; respiratory rate of 24 per minute (mpm) and pulmonary auscultation revealed fine crepitation.

Clinical examination led to investigation of possible bronchopathy and systemic causes of the ataxia. Therefore, blood count; search for hemoparasites in blood smear; serum biochemistry profile: alanine aminotransferase (ALT), gamma glutamyl transferase (GGT), albumin, globulins, urea, creatinine, urinalysis and urine protein creatinine ratio (UPC) were assessed. Abdominal ultrasonography; plain chest radiographs and contrast-enhanced radiography of the esophageal pathway (cervical and thoracic); echocardiogram and electrocardiogram were performed. A new immunochromatographic test (FIV Ac / FeLV Ag Test Kit)² for feline immunodeficiency and feline leukemia virus had negative result; glycemia was measured with a portable glucometer (Accu-Chek Active)³ and total thyroxine (T4) by chemiluminescence.

The laboratory abnormalities observed were: hemoconcentration (hematocrit 48% and 11.9 million red blood cells/mm³); azotemia (creatinine 1.8 mg/dL and urea 66 mg/dL); increased GGT (17 IU/L) and presence of red cells (+++), leucocytes (+++), bacteria (+), protein (+; UPC: 0.32) and glucose (+) in the urine sample collected through cystocentesis, even though the patient was normoglycemic (113 mg/dL).

No abnormalities were seen on abdominal ultrasonography, but thoracic radiographs (Figure 1) revealed increased radiopacity in caudal (near diaphragmatic recess/pillars) and cranial pulmonary fields, with a focal alveolar pattern, suggestive of localized pulmonary edema. There was increased radiopacity (interstitial pattern) and bronchial mineralization in other lung fields, compatible with aging changes and/or moderate chronic bronchopathy. In addition, ventral spondylosis was observed between thoracic vertebrae 11-12 and 12-13.

Contrast-enhanced (100% barium sulphate, oral) radiography showed contrast uptake at oropharyngeal and esophageal mucosa, compatible with stomatitis and esophagitis.

Echocardiography was inconclusive due to intense agitation during the exam; while the electrocardiogram (Figure 2) suggested left atrioventricular overload with increased duration of P waves and QRS complexes; no extra-systolic events were observed, and sinus rhythm was predominant, with sinus tachycardia episodes.

Based on the findings, an allergic cough due to feline asthma was suspected, and treatment was initiated with prednisolone (1 mg/kg once daily orally for 10 days). In addition, possible drug-induced esophagitis due to oral doxycycline was treated with omeprazole (0.5 mg/kg, every 24 h, orally, for 10 days) and sucralfate (250 mg every 8 h, for 10 days, orally).

Although the echocardiographic examination was inconclusive, enalapril (0.25 mg/kg, every 12 h, orally, until further recommendations) was prescribed, due to a medical history suggestive of symptomatic feline hypertrophic cardiomyopathy (lethargy, depression), and an alveolar/interstitial pattern observed on thoracic radiography. No diuretic therapy was initiated due to azotemia and proteinuria, and serial clinical and radiographic follow-ups were scheduled to monitor the alveolar pattern observed initially.

The patient was hospitalized five days after initial discharge to allow treatment during the owners' scheduled vacation. During hospital care, benazepril (0.5 mg/kg, every 24 h, orally) was prescribed instead of enalapril due to drug availability, omeprazole (1 mg/kg, every 24 h, intravenously) and prednisolone (1 mg/kg, every 24 h, orally) were continued.

On the second day of hospitalization (D2), due to the patient's difficulty swallowing on account of esophagitis, tramadol hydrochloride (2 mg/kg, every 12 h) was added for analgesia. On the same day (D2), the animal had a short episode of mixed (inspiratory and expiratory) dyspnea of approximately 60 s, unrelated to any event (manipulation or drug administration), without the concomitant or subsequent occurrence of cyanosis, tachypnea or panting.

Thoracic radiography was repeated on D2 and the alveolar radiopacity was unchanged. Furosemide (1 mg/kg, intravenously, every 24 h) was then added to prescription due to the dyspnea and radiographic findings. Later, on D4, the cat developed right hindlimb

lameness and a plantigrade gait. Therefore, methadone was included in therapy (0.2 mg/kg, h, intravenous).

On the night of D4, the cat developed signs of arterial thromboembolism in the right hindlimb, with cyanosis of pads, peripheral hypothermia and absence of pulse in the affected limb. Tachycardia and hypertension (190 mmHg) developed, hence, antiplatelet therapy was started: acetyl salicylic acid (5 mg/kg, every 72 h, orally) and clopidogrel (1/4 of a 75mg tablet every 24 h, orally). Anticoagulant therapy was also initiated with a single dose of sodium heparin (200 IU/kg, intravenously), subsequently replaced by sodium enoxaparin (1.5 mg/kg, every 6 h, subcutaneously).

Despite the use of tramadol, methadone and warm compresses on the right hindlimb for analgesia, the cat remained tachycardic (280 bpm) and a reduction in systemic arterial pressure was observed (100 mmHg).

On D6 morning, the patient was hypotensive and tachycardic (280 bpm). Volume loading test (10 mL/kg of Ringer's Lactate intravenously over 3 minutes) was performed, but the animal remained hypotensive. Therefore, a continuous infusion of dobutamine (5 µg/kg/min) was given, however, no increase in systemic pressure was observed. In the late afternoon of D6, the cat developed dyspnea, sialorrhea, prostration, oral mucosal cyanosis, intense pain and paralysis of right hindlimb. On the same day (D6), signs of arterial thromboembolism were also observed in the left hindlimb, and euthanasia was requested, with subsequent cosmetic necropsy and histopathologic examination the same night (D6).

The cause of death according to necropsy and histopathology was disseminated intravascular coagulation, possibly due to a paraneoplastic syndrome related to scirrhous pulmonary adenocarcinoma. Paralysis of the hind limbs occurred due to the presence of a saddle thrombus (Figure 3), that had partially occluded the left iliac artery and totally obstructed the right iliac artery. In addition, multiple thrombi were observed occluding the lumen of pancreatic vessels, resulting in coagulative necrosis and steatonecrosis. Arterial and venous thrombosis were observed in both kidneys, which had coalescing multifocal infarcts.

The clinical suspicion of feline hypertrophic cardiomyopathy was confirmed by the finding of myocardial hypertrophy in the left ventricle with lumen reduction of the chamber (Figure 4) and thickening of left ventricular free wall, measuring approximately

1.5 cm in the central portion. Moderate dilation of the right ventricle was also observed, with a flaccid free wall measuring approximately 0.6 cm. A thrombus was found under the mitral valve (Figure 5) and, when the route of the retrograde blood flow to the left atrium was opened, almost total occlusion of the pulmonary vein by thrombi was noted.

In the lungs, multiple infiltrating, multifocal to coalescing, neoplastic masses were observed, ranging from 0.3 to 1.5 cm, confirmed on histopathological examination to be scirrhous pattern pulmonary adenocarcinoma (Figure 6). These tumors were responsible for increased interstitial radiopacity. In addition, the radiopaque area observed in the cranial lung field of the patient's thoracic radiograph, which was suggestive of pulmonary edema, turned out to be a firm mass 3.4 cm in diameter, located at the bifurcation of the trachea, causing partial compression of the vena cava (Figure 7). This mass was identified on histopathological examination as a metastatic lung neoplasia.

Congestive liver disease with diffuse centrilobular necrosis was observed, and the spleen had diffuse pronounced congestion. It was not possible to verify changes in the central nervous system since the owner demanded the preservation of the cat's skull for burial.

DISCUSSION

Feline hypertrophic cardiomyopathy is characterized by concentric left ventricular hypertrophy, in the absence of metabolic causes or hemodynamic overload, capable of producing left ventricular wall thickening (> 6 mm diameter in diastole), without dilation [24,31].

Systemic arterial hypertension can be considered a metabolic cause of left ventricular concentric hypertrophy. An increase in vascular resistance of the left ventricular outflow tract promotes pressure overload in this chamber and, consequently, increases afterload and promotes cardiac remodeling [10]. Our patient had a discrete increase in arterial blood pressure and was classified as a prehypertensive patient [2].

The causes of systemic arterial hypertension in cats include chronic kidney disease and hyperthyroidism [2]. Feline hyperthyroidism was ruled out in this patient by a normal serum T4 value and no alterations in the thyroid gland on the histopathological evaluation. In addition, the patient had no clinical signs of this endo-

crinopathy, such as: polyphagia, hyperthermia, polyuria, polydipsia, intense vocalization and agitation [6].

About 61-65% of cats with chronic kidney disease have secondary systemic arterial hypertension [33]. The exact pathophysiologic mechanism of hypertension in chronic kidney disease has not yet been fully elucidated; however, activation of the renin-angiotensin-aldosterone system and its secretory effects of epinephrine, norepinephrine, and vasopressin, as well as the vasoconstrictive reaction and increased peripheral vascular resistance in response to these mechanisms may play a part [26].

On presentation the patient was azotemic and showed glycosuria despite being normoglycemic. These laboratory alterations classify the animal as a stage II renal patient, with borderline proteinuria and prehypertensive, according to the International Society of Renal Interest (IRIS) [14].

An ischemic etiology was suggested for the patient's renal disease, on account of the histologic evidence of multifocal thrombosis, associated with multiple areas of coagulative necrosis, and infarcted areas already replaced by fibrous connective tissue, in which thrombi were already organized and often recanalized. Thus, it was confirmed by histopathologic examination that the patient had both chronic and acute renal injuries, and these could be the cause of hypertension and left ventricular hypertrophy.

Other less frequent causes of hypertension such as acromegaly and aortic stenosis were also ruled out. Congenital heart disease was excluded because no post-mortem narrowing, or obstruction of aortic flow was found [30]. Some clinical signs frequently observed in acromegaly such as the presence of diabetes mellitus, organomegaly and prognathism were not observed in this patient [13].

The possibility of feline hypertrophic cardiomyopathy could not be excluded in this case, since echocardiographic and histopathological findings are indistinguishable between this cardiomyopathy and secondary concentric left ventricle hypertrophy [2,8,17,27]. The patient was from a breed predisposed to the development of hypertrophic cardiomyopathy [21]. Thus, to exclude this diagnosis, specific genetic tests would be necessary to identify mutations in genes encoding elements involved in cardiac contraction [1]. It is important to emphasize that there are no commercial tests available to detect these abnormalities in the Persian breed.

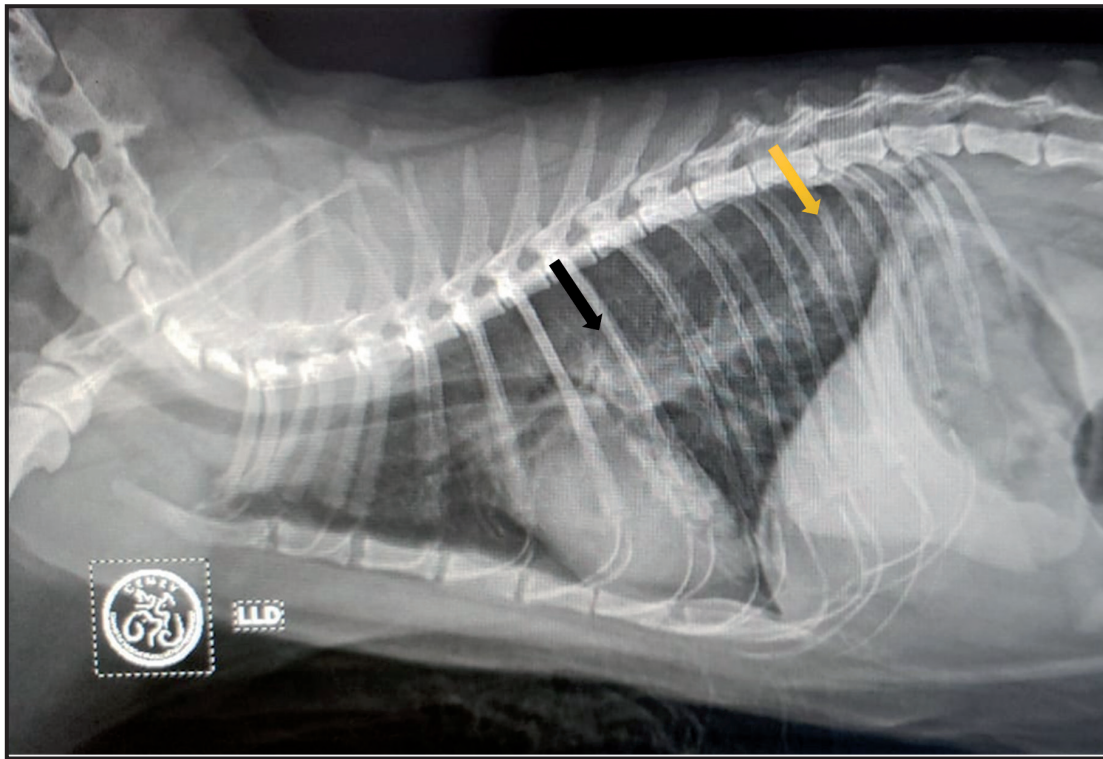


Figure 1. Right lateral-lateral thoracic radiograph of a 10-year-old Persian cat with hypertrophic cardiomyopathy and arterial and venous thromboembolism due to paraneoplastic syndrome. Radiopacity in caudal (yellow arrow) and perihilar (black arrow) lung fields are shown. A discrete alveolar pattern and pulmonary fields with increased interstitial radiopacity with bronchial mineralization can also be seen.

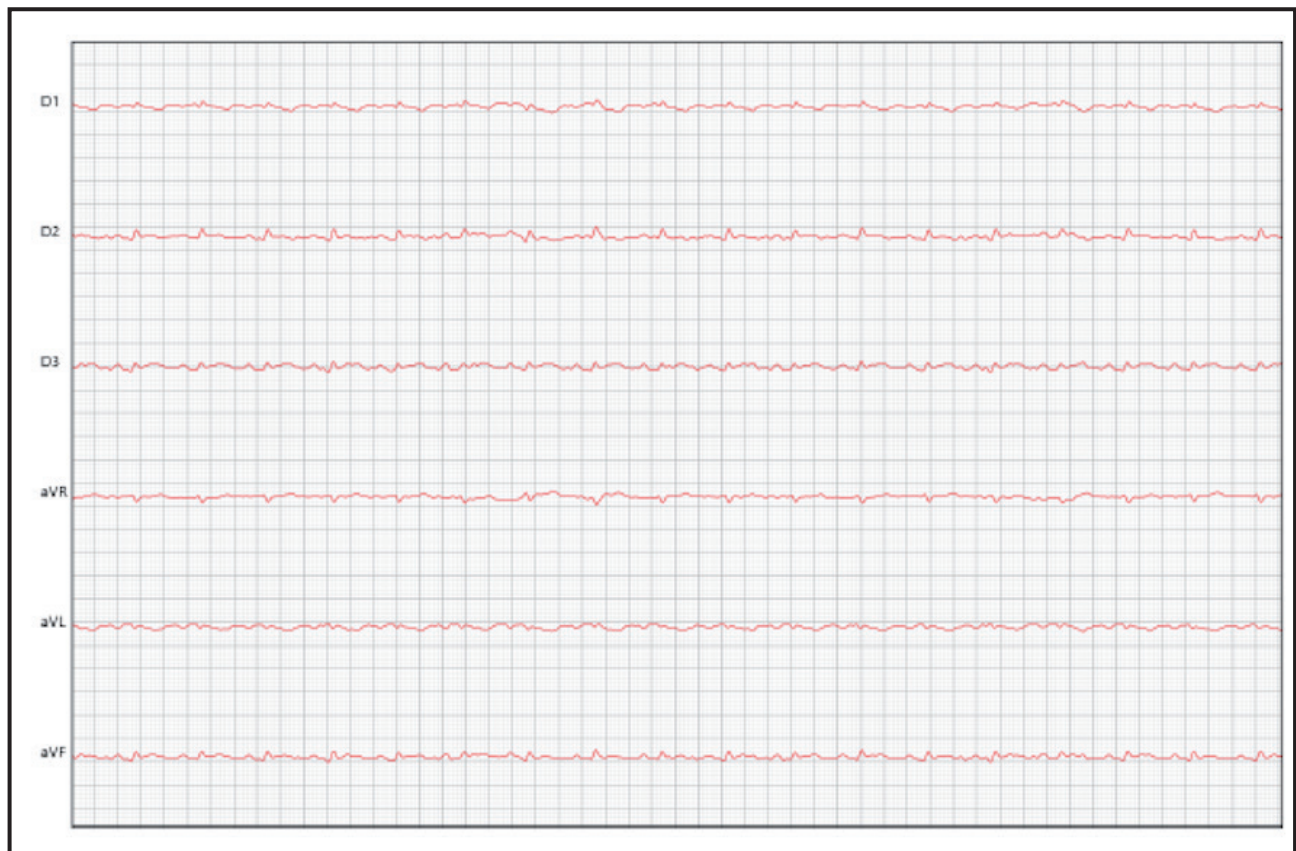


Figure 2. Electrocardiogram of a 10-year-old Persian cat with hypertrophic cardiomyopathy and arterial and venous thromboembolism due to paraneoplastic syndrome. Note the sinus rhythm and increased duration of P waves (40 ms) and QRS complex (50 ms), suggestive of left atrioventricular overload. Mean heart rate of 207 beats per minute, velocity of 50 mm/s, normal amplitude (N).

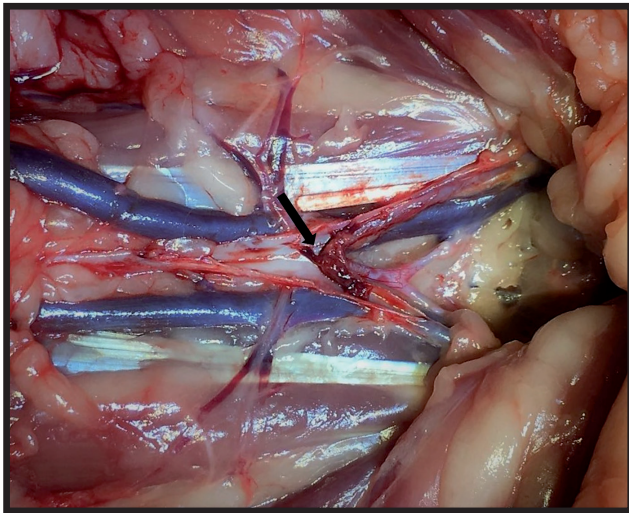


Figure 3. Abdominal cavity of a 10-year-old Persian cat with hypertrophic cardiomyopathy and arterial and venous thromboembolism due to paraneoplastic syndrome. The lumen of the abdominal aorta is observed in the bifurcation region, with the presence of a saddle thrombus (arrow), partially occluding the left iliac artery and totally obstructing the right iliac artery.

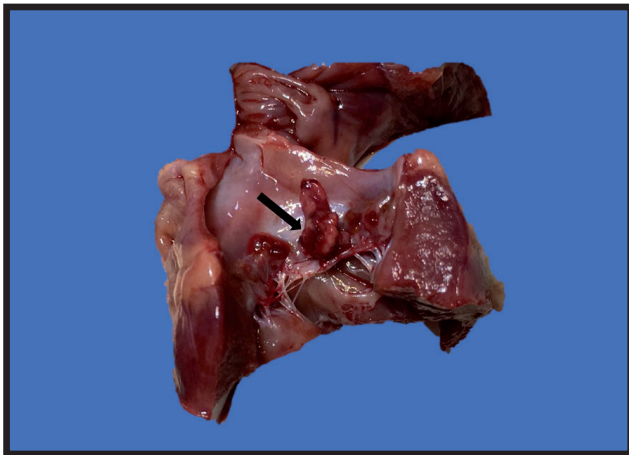


Figure 5. Presence of thrombus (arrow) above the mitral valve of a 10-year-old Persian cat with hypertrophic cardiomyopathy and arterial and venous thromboembolism due to paraneoplastic syndrome.

Other facts supported the post-mortem diagnosis of hypertrophic cardiomyopathy in this case, such as symmetric hypertrophy (1.3 cm) of the left ventricular free wall, which was greater than the mean values (0.7-0.8 cm) reported in other histopathologic studies [4,18] and the derangement between myofibrils observed in the hypertrophied tissue. Advanced cases of feline hypertrophic cardiomyopathy culminate in left heart failure due to diastolic dysfunction and mitral valve regurgitation because of structural changes in the left ventricle and its papillary muscles, or due to the anterior systolic movement of this valve [24]. These factors may lead to non-coaptation of the left atrio-ventricular valve and blood regurgitation towards the left atrium, with consequent dilation of this chamber

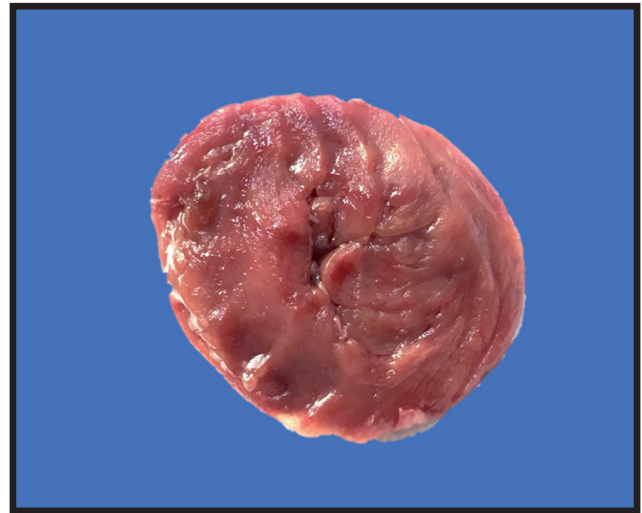


Figure 4. Transverse section of the heart of a 10-year-old Persian cat with hypertrophic cardiomyopathy and arterial and venous thromboembolism due to paraneoplastic syndrome. There is marked thickening of the left ventricular wall and consequent marked narrowing of the cardiac lumen.

and predisposition for thrombi formation due to blood stasis in this compartment [1,24].

The prognosis in cardiogenic arterial thromboembolism is poor, with survival rates around 35% [28]. Euthanasia is frequently recommended by veterinarians and represented the outcome of 91.6% of cases in a study evaluating 250 feline patients [5]. Despite administration of antithrombotic therapy with antiplatelet agents and anticoagulants [12] in this case, euthanasia was ultimately recommended due to the deterioration of the patient, with thrombotic clinical manifestations in both hind limbs, since it is known that cats with two or more limbs affected have a mortality rate of 73.6% over a period greater than 24 hours, but less than 7 days [5].

It should be noted that in the case described, despite the presence of emboli under the mitral valve and in the branch of the abdominal aorta, no dilation of the left atrium was observed, which would be essential to establish the diagnosis of arterial thromboembolism secondary to feline hypertrophic cardiomyopathy. Therefore, thrombi formation was not due to blood stasis in the left atrium, a fact supported by the presence of thrombi inside pulmonary veins, which could not be explained by the pathophysiology of hypertrophic cardiomyopathy.

Other causes of blood hypercoagulability such as hyperadrenocorticism, immune-mediated hemolytic anemia, pancreatitis, hyperthyroidism, diabetes mellitus; as well as causes of hypoalbuminemia, represented by enteropathy, sepsis, and nephropathy were ruled out based on laboratory and histopathological findings. Nephropathic animals with severe protein loss may

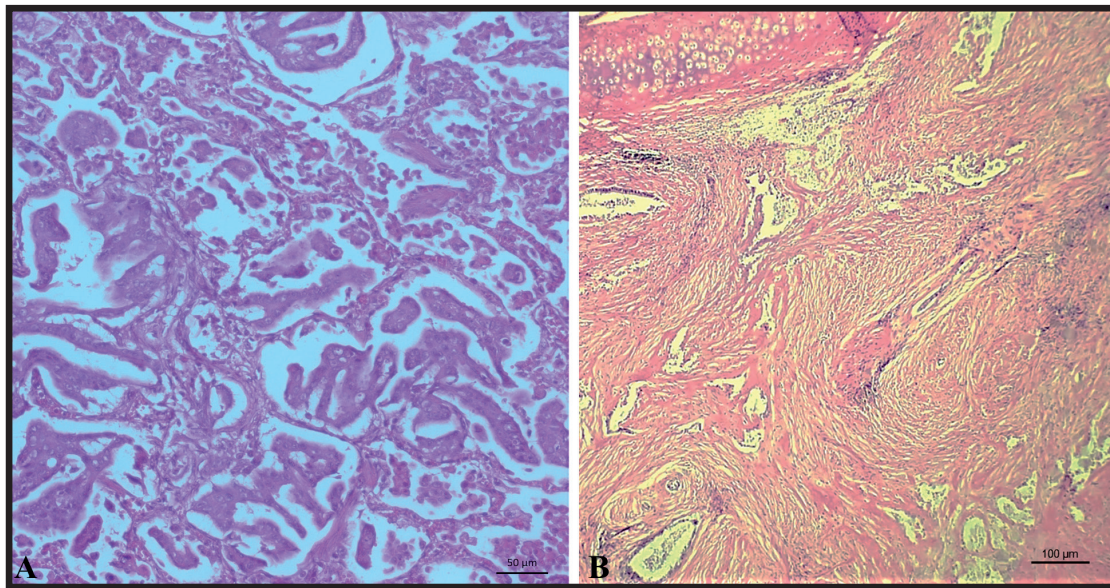


Figure 6. Histological section of the lung of a 10-year-old Persian cat with hypertrophic cardiomyopathy and arterial and venous thromboembolism due to paraneoplastic syndrome. A- Pulmonary adenocarcinoma, characterized by neoplastic masses with coalescent, multiple, well-demarcated lesions composed of epithelial cells arranged in predominantly acinar or papillary structures [HE; 10x]. B- Scirrhous areas where marked amounts of collagenous stroma are found to be slightly to moderately cellular, however abundantly collagenous [HE; 10x].

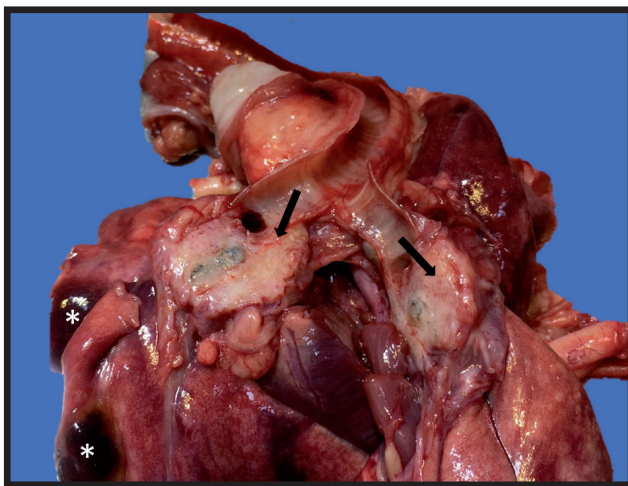


Figure 7. Firm, whitish mass at tracheal bifurcation region of a 10-year-old Persian cat with hypertrophic cardiomyopathy and arterial and venous thromboembolism due to paraneoplastic syndrome. The mass was 3.4 cm diameter, did not invade the tracheal lumen, however it partially compressed vena cava (arrows). Multiple foci of pulmonary infarction (*) due to neoplastic emboli.

present with coagulation disorders, but the cat had mild proteinuria and no glomerular lesions on the histopathological analysis.

Hence, the thromboembolism in this patient could only be explained by the presence of pulmonary adenocarcinoma, which was a triggering factor for disseminated intravascular coagulation and multiple thrombus formation, both in arterial and venous beds. It is known that tumor cells can have paraneoplastic effects, such as direct and indirect activation of the coagulation cascade, and more than 90% of human patients with metastasis may present with coagulative disorders [20].

Cancer patients have high levels of fibrinopeptide A, thrombin fragments and thrombin-anti-thrombin complex, and also produce oncological pro-coagulant factor and inhibitory factors of fibrinolysis. This set of elements plays a key role in the hypercoagulability observed in lung neoplasms, besides contributing to tumor angiogenesis and subsequent neoplastic growth and dissemination [20]. In dogs and cats, neoplasms also play an important role as the cause of thrombosis [3,34]. In the study performed by Smith *et al.* [28], 5% of the cats with arterial thromboembolism had a neoplasm as the underlying cause of thromboembolism; other authors have specifically identified the presence of lung tumors in feline patients with arterial thromboembolism [11,16,23].

It is assumed that the concomitant occurrence of feline hypertrophic cardiomyopathy and lung cancer may be underdiagnosed, since both diseases may cause similar clinical signs, such as cyanosis, lethargy, and dyspnea; and may both progress to thrombosis. In addition, anticoagulants such as heparin, frequently used in the treatment of arterial thromboembolism, also exhibit antitumor effect, preventing the binding of neoplastic cells to platelets and endothelium; inhibiting tumor angiogenesis; and also regulating the immune system function, modulating cytokines and migration of leukocytes that aid in malignant cells destruction [15,19,20]. Therefore, the therapy used for arterial thromboembolism benefits human patients with pulmonary malignant tumor [15] and could conceal clinical signs and delay suspicion of feline lung neoplasia.

Hence, feline hypertrophic cardiomyopathy should be suspected in cats with thromboembolism, however we suggest that a thorough screening (including sensitive imaging exams, such as radiography, computed tomography or magnetic resonance) should be performed in older cats to rule out respiratory conditions; based on the fact that radiographic findings of lung neoplasia may mimic pulmonary edema or resemble chronic bronchopathy, a respiratory disease frequently seen in cats in this age group.

MANUFACTURERS

¹Medmega Indústria e Equipamentos Médicos Ltda. Franca, SP, Brazil.

²Alere (Abbot). São Paulo, SP, Brazil.

³Roche Diabetes Care Brasil Ltda. Jaguaré, SP, Brazil.

Acknowledgements. We are thankful for the veterinarians from Mania de Gato Veterinary Clinic, veterinarians of the Intensive Care Unit (ICU) and Imaging sector from Centro de Especialidades Médico Veterinário (CEMEV); Teacher Veronica Jorge Babo Terra from Federal University of Mato Grosso do Sul and the tutor Priscila for kindly have authorized the report of the case of her beloved feline.

Declaration of interest. The authors report no conflicts of interest. The authors alone are responsible for the content and writing of the paper.

REFERENCES

- 1 **Abbott J.A. 2010.** Feline hypertrophic cardiomyopathy: an update. *Veterinary Clinics of North America - Small Animal Practice*. 40(4): 685-700.
- 2 **Acierno M.J., Brown S., Coleman A.E., Jepson R.E., Papich M., Stepien R.L. & Syme H.M. 2018.** ACVIM consensus statement: Guidelines for the identification, evaluation, and management of systemic hypertension in dogs and cats. *Journal of Veterinary Internal Medicine*. 32(6): 1803-1822.
- 3 **Bergman P.J. 2007.** Paraneoplastic syndromes. In: Whitrow S.J. & Vail D.M (Eds). *Whitrow & MacEwen's Small Animal Clinical Oncology*. 4th edn. St Louis: Saunders Elsevier, pp.77-93.
- 4 **Biasato I., Francescone L., La Rosa G. & Tursi M. 2015.** Anatomopathological staging of feline hypertrophic cardiomyopathy through quantitative evaluation based on morphometric and histopathological data. *Research in Veterinary Science*. 102: 136-141.
- 5 **Borgeat K., Wright J., Garrod O., Payne J.R. & Fuentes V.L. 2014.** Arterial thromboembolism in 250 Cats in general practice: 2004-2012. *Journal of Veterinary Internal Medicine*. 28(1): 102-108.
- 6 **Carney H.C., Ward C.R., Bailey S.J., Bruyette D., Dennis S., Ferguson D., Hinc A. & Rucinsky A.R. 2016.** AAFP Guidelines for the management of feline hyperthyroidism. *Journal of Feline Medicine and Surgery*. 18(5): 400-416.
- 7 **Ferasin L., Sturgess C.P., Cannon M.J., Caney S.M.A., Gruffydd-Jones T.J. & Wotton P.R. 2003.** Feline idiopathic cardiomyopathy: A retrospective study of 106 cats (1994-2001). *Journal of Feline Medicine and Surgery*. 5(3): 151-159.
- 8 **Fox P.R. & Schober K.A. 2015.** Management of asymptomatic (occult) feline cardiomyopathy: challenges and realities. *Journal of Veterinary Cardiology*. (17): S150-S158.
- 9 **Fox P.R. 2003.** Hypertrophic cardiomyopathy. Clinical and Pathologic Correlates. *Journal of Veterinary Cardiology*. 5(2): 39-45.
- 10 **Franchini K.K.G. 2001.** Hipertrofia cardíaca: mecanismos moleculares. *Revista Brasileira de Hipertensão*. 8(1): 125-142.
- 11 **Hogan D.F. 2017.** Feline Cardiogenic Arterial Thromboembolism: Prevention and Therapy. *Veterinary Clinics of North America - Small Animal Practice*. 47(5): 1065-1082.
- 12 **Hogan D.F., Dhaliwal R., Sisson D. & Kitchell B. 1999.** Paraneoplastic thrombocytosis-induced systemic thromboembolism in a cat. *Journal of the American Animal Hospital Association*. 35(6): 483-486.
- 13 **Hurty C.A. 2005.** Feline Acromegaly: a review of the syndrome. *Journal of the American Animal Hospital Association*. 41: 292-297
- 14 **International Renal Interest Society. 2017.** IRIS Staging of CKD (modified 2017). [Fonte:<http://www.iriskidney.com/pdf/IRIS_2017_Staging_of_CKD_09May18.pdf>]. [Accessed online in December 2019].
- 15 **Kim J.Y., Al-Hilal T.A., Chung S.W., Kim S.Y., Ryu G.H., Son W.C. & Byun Y. 2015.** Antiangiogenic and anticancer effect of an orally active low molecular weight heparin conjugates and its application to lung cancer chemoprevention. *Journal of Controlled Release*. 199: 122-131.

- 16 **Laste N.J. & Harpster N.K. 1993.** A retrospective study of 100 cases of feline distal aortic thromboembolism: 1977-1993. *Journal of American Animal Hospital Association*. 31: 492-500.
- 17 **Lesser M., Fox P.R. & Bond B.R. 1992.** Assessment of hypertension in 40 cats with left ventricular hypertrophy by Doppler-shift sphygmomanometry. *Journal of Small Animal Practice*. 33(2): 55-58.
- 18 **Liu S.K., Maron B.J. & Tilley L.P. 1981.** Feline hypertrophic cardiomyopathy: gross anatomic and quantitative histologic features. *The American Journal of Pathology*. 102(3): 388-395.
- 19 **Lunsford K.V. & Mackin A.J. 2007.** Thromboembolic Therapies in Dogs and Cats: An Evidence-Based Approach. *Veterinary Clinics of North America - Small Animal Practice*. 37(3): 579-609.
- 20 **Marinho F.C.A. & Takagaki T.Y. 2008.** Artigo de revisão: Hipercoagulabilidade e câncer de pulmão. *Jornal Brasileiro de Pneumologia*. 34(5): 312-322.
- 21 **Martin L., VandeWoide S., Boon J. & Brown D. 1994.** Left ventricular hypertrophy in a closed colony of Persian cats. *Journal of Veterinary Internal Medicine*. 8: 143.
- 22 **Meurs K.M., Norgard M.M., Kuan M., Haggstrom J. & Kittleson M. 2009.** Analysis of 8 sarcomeric candidate genes for feline hypertrophic cardiomyopathy mutations in cats with hypertrophic cardiomyopathy. *Journal of Veterinary Internal Medicine*. 23: 840-843.
- 23 **Moore K.E., Morris N., Dhupa N., Murtaugh R.J. & Rush J.E. 2000.** Retrospective study of streptokinase administration in 46 cats with arterial thromboembolism. *Journal of Veterinary Emergency and Critical Care*. 10(4): 245-257.
- 24 **Pellegrino A. & Daniel A.G.T. 2011.** Cardiomiopatia hipertrófica em felinos - aspectos diagnósticos e terapêuticos. *Vets Today*. 11: 1-3.
- 25 **Reina-doreste Y., Stern J.A., Keene B.W., Atkins C., Defrancesco T.C, Ames M.K, Hodge T.E. & Meurs K.M. 2014.** Effects of Pimobendan on survival time in cats with hypertrophic cardiomyopathy and congestive heart failure. *Scientific Reports*. 245(5): 534-539.
- 26 **Ross L. 1992.** Hypertension and chronic renal failure. *Seminars in Veterinary Medicine and Surgery (small animal)*. 7(3): 221-226.
- 27 **Sampedrano C.C., Chetboul V., Gouni V., Nicolle A.P., Pouchelon J.L. & Tissier R. 2006.** Systolic and Diastolic Myocardial Dysfunction in Cats with Hypertrophic Cardiomyopathy or Systemic Hypertension. *Journal of Veterinary Internal Medicine*. 20(5): 1106-1115.
- 28 **Smith S.A. & Tobias A.H. 2004.** Feline arterial thromboembolism: An update. *Veterinary Clinics Small Animal Practice*. 34(5): 1245-1271.
- 29 **Smith S.A., Tobias A.H., Jacob K.A., Fine D.M. & Grumbles P.L. 2003.** Arterial Thromboembolism in Cats: Acute Crisis in 127 Cases (1992-2001) and Long-Term Management with Low-Dose Aspirin in 24 Cases. *Journal of Veterinary Internal Medicine*. 17(1): 73-83.
- 30 **Sousa M.G., Paulo J., Pascon E., De Brum A.M., Santos P.A.C. & Camacho A.A. 2007.** Severe aortic stenosis in a Persian kitten. *Revista Portuguesa de Ciências Veterinárias*. 103(567-568): 229-232.
- 31 **Spalla I., Locatelli C., Riscazzi G., Santagostino S., Cremasch E. & Brambilla P. 2016.** Survival in cats with primary and secondary cardiomyopathies. *Journal of Feline Medicine and Surgery*. 18(6): 501-509.
- 32 **Spalla I., Payne J.R., Borgeat K., Luis Fuentes V. & Connolly D.J. 2017.** Prognostic value of mitral annular systolic plane excursion and tricuspid annular plane systolic excursion in cats with hypertrophic cardiomyopathy. *Journal of Veterinary Cardiology*. 20(3): 154-164.
- 33 **Stiles J., Polzin D.J. & Bistner S.J. 1994.** The prevalence of retinopathy in cats with systemic hypertension and chronic renal failure or hyperthyroidism. *Journal of the American Animal Hospital Association*. 30: 564-572.
- 34 **Vilar Saavedra P., Lara García A., Zaldívar López S. & Couto G. 2011.** Hemostatic abnormalities in dogs with carcinoma: A thromboelastographic characterization of hypercoagulability. *Veterinary Journal*. 190(2): 78-83.